

Studies of a novel photosensitizer Pd-bacteriopheophorbide (Tookad[®]) for the prostate cancer PDT in canine model

Zheng Huang^{*1}, Qun Chen¹, Pierre-Herve Brun², Brian C. Wilson³, Avigdor Scherz⁴
Yoram Salomon⁴, David Luck¹, Jill Beckers¹ and Fred W. Hetzel¹

¹HealthONE Alliance, Denver, CO, USA; ²Steba Biotech, Toussus-Le-Noble, France

³Ontario Cancer Institute, Toronto, Canada; ⁴Weizmann Institute of Science, Rehovot, Israel

ABSTRACT

Photodynamic therapy (PDT) mediated with vascular acting photosensitizer pd-bacteriopheophorbide (Tookad[®]), is investigated as an alternative modality for the total ablation of prostate cancer. *In vivo* normal canine prostate is used as the animal model. Interstitial PDT was performed by irradiating the surgically exposed prostates with a diode laser (763 nm, 150 mW/cm) to activate the i.v. infused photosensitizer drug. The effects of two-session PDT were evaluated. The prostate and its adjacent tissues were harvested and subjected to histopathological examination. At one-week, post second-session PDT, the animals recovered well with little or no urethral complications. Prostatic urethra and prostate adjacent tissues (bladder and underlying colon) were well preserved. Two-session PDT or one single session PDT induced a similar extent of damage. PDT induced prostate lesions were characterized by marked hemorrhagic necrosis. Maximum lesion size of over 3 cm in dimension could be achieved with a single 1-cm interstitial treatment, suggesting the therapy is very effective in ablating prostatic tissue. Pharmacokinetic studies show that the photosensitizer is cleared rapidly from the circulation. In conclusion, the novel photosensitizer Tookad mediated PDT may provide an effective alternative to treat prostate cancer.

Keywords : photodynamic therapy, prostate cancer, tissue response, pharmacokinetics, vascular effects

1. INTRODUCTION

In the United States, prostate cancer is the most common male cancer and the second leading cause of cancer death among men (1). Prostate specific antigen (PSA) screening increases the diagnosis of early stage cancers when they are confined to the prostate gland. Surgery, radiation and hormone therapy or their combinations are primary options. Significant side effects, such as impotency, urinary incontinence and injuries to nearby structures, are often associated with these modalities (2, 3). Other less invasive approaches, such as cryotherapy, hyperthermia, focused ultrasound or focused extracorporeal pyrotherapy, have been developed for the localized prostate cancer (4-7). However, the clinical outcome of these approaches are comparable to that of radiotherapy or radical prostatectomy (4, 8). An alternative to treat localized prostate cancer is thus desired, either for a primary cancer or organ confined recurrent cancer.

Photodynamic therapy (PDT), an increasingly practiced cancer treatment modality, involves administering a photosensitizer drug then activating the drug with light of the appropriate wavelength. The feasibility of using PDT to treat localized prostate cancer on animal models has been investigated in this laboratory as well as several others. Canine prostate has been used as an animal model for studying PDT in prostate due to its resemblance both in physical size and in anatomical structure to that of human. Canine prostate tissue-responses to PDT mediated by various photosensitizer agents were investigated (9-18). Previous studies indicate that PDT is a feasible modality in the destruction of localized prostate cancer and total ablation of the prostate gland. However, its effectiveness depends on the pharmacokinetics and absorption spectrum of the photosensitizer drug.

The present work is a preclinical study utilizing a second-generation photosensitizer, Tookad (Pd-bacteriopheophorbide, also known as WST09) to ablate prostatic tissue. Our previous study (9, 10) showed that Tookad-PDT can destroy a clinically significant volume of prostate tissue with preservation of adjacent tissues (bladder and underlying colon). The current Tookad PDT human clinical trial is a standard drug/light dose escalation trial. The subjects will be those recurrent patients who failed radiation therapy. Some subjects who received low dose are eligible to receive a second full dose treatment. In this study, we evaluate the effects of two-session PDT and Tookad pharmacokinetics in the established canine model. Although, many parameters regarding the optimal photosensitizer and light combination to give maximum ablation of malignant tissue still remain to be elucidated, the results obtained from this and the previous translational study have demonstrated a unique vasculature targeting property and provided valuable data for the design of ongoing Tookad-PDT human clinical trials.

2. MATERIALS AND METHODS

2.1 Animal model

A total of 19 adult healthy Beagles (2 ~ 9 years old, 10 ~ 18 kg) were studied. The animals were obtained from licensed vendors (Marshall Farms, North Rose, NY, USA or Harlan Farm, Indianapolis, IN, USA) and conditioned for a minimum of one week before any experimental procedures were carried out. All studies were performed under the guidance of the Institutional Care and Use Animal Committee at HealthONE Alliance. The prostate in these animals is typically ~ 3 cm in lateral diameter.

2.2 Premedication

Benadryl (i.v. 0.7 ~ 1.4 mg/kg) and Dexamethasone (SQ, 2 mg per dog) were given 24 h prior to and immediately prior to the photosensitizer infusion to counteract the effect of the co-solvent Cremophor EL-P of the photosensitizer drug on blood pressure.

2.3 Photosensitizer

Photosensitizer drug Tookad (Palladium-Bacteriopheophorbide, molecular weight 715; STEBA BIOTECH, France) was prepared in a Cremophor EL-P based vehicle by the manufacturer. The concentration of Tookad (5.0 mg/ml or 2.5 mg/ml) was determined spectroscopically at 763 nm using extinction coefficient of 10.86×10^4 . Tookad was given to the animal at dosages of 0.25, 1 and 2 mg/kg, respectively, via a slow i.v. infusion through the right cephalic vein catheter under the dimmed ambient lighting.

2.4 Light source

The light source was a portable 763 nm diode laser (CeraLas, CeramOptec, Bonn, Germany) with a maximum output power of 4 W and a calibration port for determining delivered output power. The laser output was directly coupled into a beam splitter (Fiber Splitter-400 micron, Ocean Optics Inc., Dunedin, FL, USA) that allowed two sites to be treated simultaneously. The light fluence of 150 mW/cm was delivered through a diffuser tip of cylindrical fiber (10 mm active length, 1.3 mm diameter; Model CD 603-10C; CeramOptec, Germany). The diffuser tip was inserted in the middle of anterior section and approximately 1 cm away from urethra.

2.5 Surgical and PDT procedures

Standard sterilization procedures were strictly followed. All surgical instruments were autoclaved and invasive probes chemically sterilized. As an extra precaution, the dogs received antibiotics before and after surgery (IM, Ampicillin, 20 mg/kg) to prevent possible infection. Pain control consisted of pre-operative and post-operative injection of morphine with long term control provided by Fentanyl patches. All dogs were prepared for surgery following a standard canine laparotomy procedure (9).

Tookad (0 - 2 mg/kg) was administered by slow infusion through an i.v. catheter at a constant rate of 2.5 mg/min (drug concentration 5 mg/ml, drug dose 2 mg/kg) or at various rates of 0.25 – 2 mg/min (drug concentration 2.5 mg/ml, drug dose 0.25 – 5 mg/kg) over a period of 10 min. Light was applied during the drug infusion or 5 - 15 min after the completion of the infusion. When light was applied during infusion, PDT light irradiation was applied

4 min after the onset of drug infusion, and there was an approximate 6 min overlap between drug infusion and light irradiation. For interstitial irradiation 50, 100 or 200 J/cm was delivered. Irradiation lasted approximately 6 – 22 min in each animal.

For two-session PDT, the first session was carried out by a combination of a lower drug dose (0.25 mg/kg) or an intermediate drug dose (1 mg/kg) with lower light dose (50 J/cm) or intermediate light dose (100 J/cm). For each treatment session, both lobes received an identical light dose. The second session was carried out three months later, which was carried out by a combination of an intermediate or high drug dose (2 mg/kg) with high light dose (200 J/cm) or intermediate light dose. In the second session, a diffuser fiber was inserted into the same location of the first treatment.

Immediately following PDT treatment, the rectus muscle, fascia and skin were closed with interrupted sutures. The endotracheal tube was removed upon recovery of the swallow reflex. The i.v. catheter was either removed immediately after surgery or left for drawing blood samples. Standard procedures were followed for animal care. After surgery the dogs were kept in dimmed ambient lighting for 2 – 4 h. Urinalysis was performed for 24 – 48 h post PDT.

2.6 Pharmacokinetics

Prostate biopsy samples (10 - 50 mg) were taken before or after drug infusion (2 mg/kg, fixed infusion rate) and after the completion of light irradiation. The samples were homogenized in double distilled water, lyophilized in test tubes followed by addition of 0.4 ml of 70% HNO₃ and incubated at room temperature overnight and then 90 °C for 1 hour. The samples were diluted in double distilled water to 10 ml. Tookad-Palladium ion concentrations were determined by an Inductive Coupled Plasma Mass Spectroscopy. Background was determined for each dog from samples taken prior to drug infusion, and values were subtracted accordingly.

Blood samples (~1 ml) were taken from the left jugular vein before drug infusion (2 mg/kg, fixed infusion time) and every 5 min after the onset of drug infusion, then at 2, 4, 12, 24, 48, 72 and 168 hours post infusion. The samples were lyophilized in test tubes followed by addition of 0.4 ml of 70% HNO₃ and incubated at room temperature overnight and then at 90 °C for 1 hour. The samples were diluted in double distilled water to 20 ml. Tookad-Palladium ion concentrations were determined by an Inductive Coupled Plasma Mass Spectroscopy as described above.

2.7 Histopathologic examination

At necropsy, the prostate, bladder and underlying colon section site were removed and photographed. The prostate was dissected from the urinary bladder. All specimens were fixed in 10% neutral buffered formalin. The prostate, bladder, and colon were cut into 3 mm blocks, photographed, and embedded in paraffin. Sections of 5 µm thickness were stained with standard H&E and special Dyer's Verhoeff Variation (19) to examine the histopathological changes.

3. RESULTS

3.1 Pharmacokinetics examination.

Prostate biopsy and blood samples were collected and analyzed by ICP-Mass Spectroscopy for the palladium concentration to determine the Tookad concentration. The pharmacokinetics data of blood samples indicate a build-up of Tookad in the circulation during the time window of light irradiation (5 – 50 min from the onset of drug infusion), with subsequent rapid clearance to background levels after 24 h (Fig. 1).

Prostate biopsy (tissue + blood) was obtained after the completion of drug infusion and before or after PDT. The results consistently showed a lower tissue Tookad concentration compared to that in the blood circulation. At the

completion of PDT or 35 min after drug injection, the Tookad-Pd level in blood was 392 ± 88 ng/g ($n=3$) compared to 54 ± 36 ng/g ($n=6$) in prostatic tissue. The concentration of samples taken at 25 or 35 min after the completion of infusion were slightly higher than that of samples taken at 5 min after the completion of infusion (Fig. 2). This was inconsistent with the blood concentration but implied that the prostate gland maintained a high level of Tookad after the completion of drug infusion and during the course of PDT.

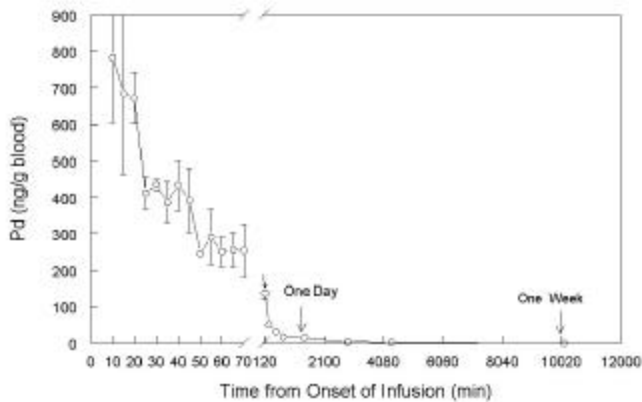


Figure 1. Tookad pharmacokinetic. Data points are average of triplicates \pm STD. Tookad concentration (as measured by its Pd component) as a function of time. Light irradiation was applied between 5 – 50 min after the onset of drug infusion.

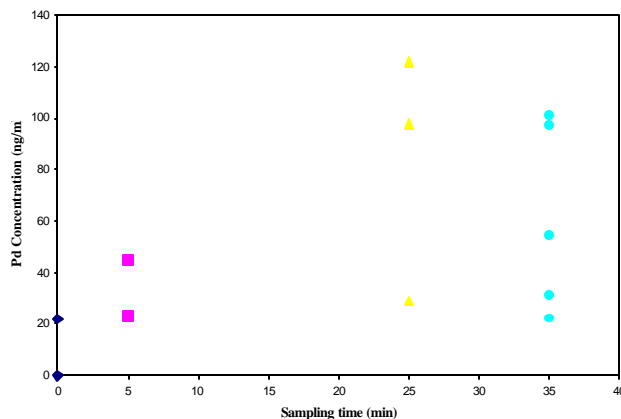


Figure 2. Prostate Tookad-Pd concentrations. Prostate biopsy (tissue+blood) was taken after the completion of drug infusion (time = 0) and before PDT (time = 5 min) or after PDT (time = 25 or 35 min). Tookad-Pd concentration was measured by ICP-MS. The concentrations in post-PDT samples were higher than that of pre-PDT samples.

3.2 Post-surgical observations.

The surgical wound healed well in all treated dogs, with no post-PDT urethral complications. One dog showed urinary retention during the first 24 h after the second session PDT. Urinalysis indicated trace blood (+1 – +4) in the urine samples post two-session PDT within the first 24 – 48 h, but none required medical attention or treatment.

3.3 Histopathological findings.

Macroscopic findings. At one week post the second treatment of two-session PDT, the typical lesion pattern of a combination of an intermediate drug/light dose of 1st treatment and a high drug/light dose of 2nd treatment was the mixture of necrotic lesion, severe or mild hemorrhage from the second treatment and residual fibrosis from the first treatment (Fig. 3). This implies that TOOKAD PDT can destroy fibrotic tissue formed from the first treatment. The PDT-induced lesions were well delineated from the adjacent normal tissue, and the zone of necrosis increased with

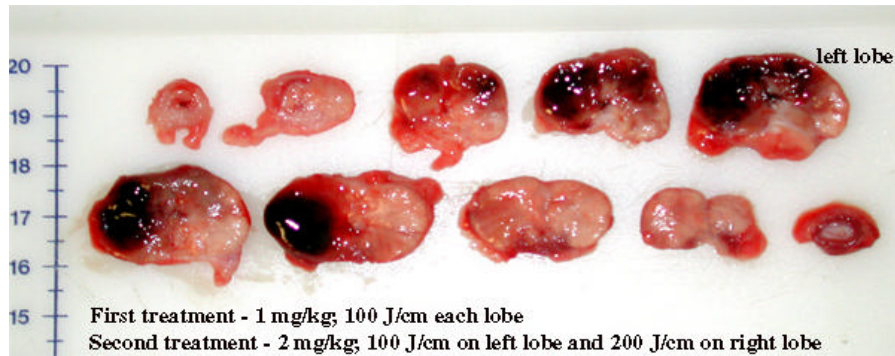


Figure 3. The dissect view of prostate gland after two-session PDT. Typical lesion pattern of a combination of an intermediate drug/light dose of 1st treatment and a high drug/light dose of 2nd treatment – the mixture of necrotic lesion, severe or mild hemorrhage from the second treatment and residual fibrosis from the first treatment.

the increase of the delivered light fluence and drug dose. The lesion pattern of a combination of low drug/light dose of 1st treatment and a high drug/light dose of 2nd treatment is identical to single high light/drug dose treatment.

Microscopic Findings. Figure 4 shows a mixture of patchy or diffused hemorrhage, necrosis, inflammation, degeneration of fibrotic tissue and residual fibrosis lesions induced by a combination of intermediate drug/light dose of the first session PDT and high drug/light dose of the second session PDT. The lesion pattern is very different to that of single PDT treatment. There is not a clear transitional change from total necrosis to hemorrhage. The remaining glandular-like structure is still visible in the hemorrhagic necrosis region. Residual collagen deposition and fibrosis are visible. The lesion is characterized by, as shown in following pictures.

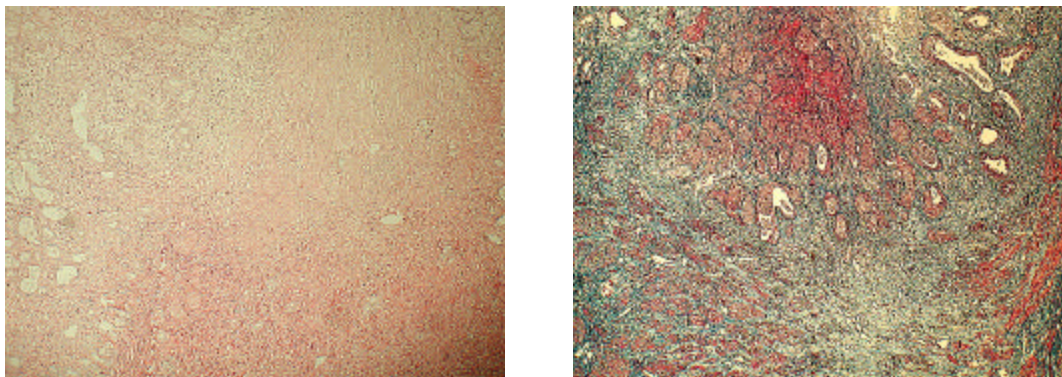


Figure 4. The microscopic view of prostate gland after two-session PDT. Typical lesion pattern of a combination of an intermediate drug/light dose of 1st treatment and a high drug/light dose of 2nd treatment – total necrosis and destruction of glandular and connective tissue at the center of irradiated volume, patchy or diffused hemorrhage from the second treatment and residual fibrosis formed after the first treatment (left: H&E; right: Verhoeff).

4. DISCUSSION

The application of PDT to treat prostate cancer on animal models as well as human patients has been investigated for the past decade. Canine prostate tissue-responses to PDT mediated by various photosensitizers have been investigated (13-18) and the general consensus is that, given a fixed optical dose, the value of dynamic light fluence and the volume of tissue damage are rather unpredictable. The implementation of PDT in prostate cancer treatment is limited by the inaccurate or insufficient control of treatment volume, mainly due to poor optical dosimetry and slow clearance of currently available photosensitizer(s). Our previous study (9, 10) suggests that Tookad-based PDT may overcome these problems due to its absorption spectrum and vascular acting property, and thereby may provide an effective alternative/adjunctive modality to treat prostate cancer. This study further demonstrates the feasibility and effectiveness of Tookad-PDT for treatment of prostate cancer. The observations obtained from this study are directly relevant to designing and optimizing future clinical use of the Tookad-PDT against prostate cancer.

The value of dynamic light fluence measured during Tookad-PDT is relatively stable and the attenuation depth is estimated at 4 mm range (10). Nevertheless, it is also encouraging that the effect of Tookad-PDT on the urethra was minimal, both functionally and structurally, even when the urethra was within the treatment area and the periurethral prostate tissue was destroyed. This was not the case with Photofrin (12-14) or other tested photosensitizers (15-18) and may be related to the Tookad mechanisms of vascular targeting.

In contrast to many photosensitizers being investigated clinically for prostate cancer (20-22), Tookad-PDT is believed to be purely vascularly mediated while in the blood circulation shortly after the i.v. infusion. The clearance of Tookad from the circulation is very fast and its plasma half-life is less than 1 h in a mouse model (unpublished data). Similarly, this study also shows a rapid clearance of Tookad in the canine model (Fig. 1). The results indicate a short period of build-up of Tookad in the circulation during the PDT time window of 0 – 50 min from the onset of drug infusion. Consistent with this, rapid clearance has been observed in several other tissues (including tumor, skin) measured in *in vivo* models of other animals (23). Bourre *et al* demonstrated recently that there is little uptake of Tookad by tumor but a gradual accumulation of Tookad in liver in a mouse model (24). Prostate biopsy analysis of this study indicates that there is little Tookad uptake by prostatic tissue. However, there is slight increase in Tookad concentrations in prostate during the course of light irradiation (Fig. 2), which indicates that the light can be applied within a short time after (or even during) drug administration while the circulating drug concentration is relatively high. For interstitial prostate PDT this has the significant practical advantage that the light may be delivered during or shortly after drug administration to complete PDT as a single operative session in a short period. The fast clearance also significantly reduces the risk of phototoxicity. Hence, the post-treatment management should be considerably simplified for a patient receiving Tookad-PDT.

In this study, two-session Tookad PDT induced lesions were evaluated by H&E and collagen staining. The lesion characteristics of a combination of low drug/light dose of 1st treatment and a high drug/light dose of 2nd treatment is identical to single high light/drug dose treatments. The typical lesion pattern of a combination of an intermediate drug/light dose of 1st treatment and a high drug/light dose of 2nd treatment is the mixture of severe necrosis, patchy and diffused hemorrhage from the second treatment and residual fibrosis from the first treatment (Fig. 3 and 4). This implies that TOOKAD PDT can destroy fibrotic tissue formed 3 months after the first treatment.

One of the advantages of Tookad-PDT is its being activated at a relatively long wavelength (763 nm), with corresponding greater light attenuation depth (~ 4 mm) in prostatic tissue (10). Tookad-PDT induces much larger prostate lesions than other photosensitizers, which implies Tookad-PDT can be delivered under precise control and therefore a predictable treatment outcome can be expected.

In conclusion, these results suggest that Tookad-PDT, utilizing a second-generation photosensitizer with an activation wavelength at the near-infrared, with a short waiting period between drug administration and light irradiation and fast photosensitizer clearance from the body, acting primarily upon vasculature, may provide an alternative/adjunctive modality to treat early stage primary prostate cancer and recurrent diseases (e.g. post radiation therapy failure).

Acknowledgement

This project was supported in part by STEBA BIOTECH (France) and by a NIH grant PO1-CA43892.

REFERENCES

1. Boyle P. Prostate cancer 2000: Evolution of an epidemic of unknown origin; in Prostate Cancer 2000, Ed. L. Denis, Springer-Verlag, Herdelberg, 5-11, 2001.
2. Catalona W. J. (1994) Management of cancer of the prostate. *New Eng. J. Med.* **331**:996-1004.
3. Stamey T.A. (1993) Irradiation as primary treatment for prostate cancer. *Am. Urol. Assoc. Today* **6**:14.
4. Onik G. (2001) Image-guided prostate cryosurgery: state of the art. *Cancer Control* **8**:522-531.
5. Yerushalmi A. (1998) Localized non-invasive deep microwave hyperthermia for the treatment of prostatic tumours: the first 5 years. In "Application of hyperthermia in the treatment of cancer" Ed. by R. D. Issels and W. Wilmanns, Berlin, Springer Verlag, p 141.
6. Gelet A., J. Y. Chapelon, R. Bouvier, O. Rouviere, D. Lyonnet and J. M. Dubernard (2001) Transrectal high intensity focused ultrasound for the treatment of localized prostate cancer: factors influencing the outcome. *Eur. Urol.* **40**:124-192.
7. Vallancien G., et al., (1991) Focused extracorporeal pyrotherapy: experimental results. *Eur., Urol.* **20**: 211-219.
8. Chaussy C. and S. Thuroff (2001) Results and side effects of high-intensity focused ultrasound in localized prostate cancer. *J. Endourol.* **15**:437-440.
9. Chen Q., Z. Huang, D. Luck, J. Beckers, P. Brun, B. C. Wilson, A. Scherz, Y. Salomon and F. W. Hetzel (2002) WST09 (TOOKAD) mediated photodynamic therapy as an alternative modality in treatment of prostate cancer. *Proc. SIPE.* **4612**:29-39.
10. Chen Q., Z. Huang, D. Luck, J. Beckers, P. Brun, B. Wilson, A. Scherz, Y. Salomon, F. Hetzel (2002) Preclinical studies in normal canine prostate of a novel Palladium-bacteriopheophorbide (WST09) photosensitizer for photodynamic therapy of prostate cancer. *Photochem. Photobiol.* **76**:88-95.
11. Chen Q. and F. W. Hetzel (1998) Laser dosimetry studies in the prostate. *J. Clin. Laser Med. Surg.* **16**:9-12.
12. Chen Q., B. C. Wilson, S. D. Shetty, M. S. Patterson, J. C. Cerny and F. W. Hetzel (1997) Changes in *in vivo* optical properties and light distributions in normal canine prostate during photodynamic therapy. *Radiat. Res.* **147**:86-91.
13. Lee L. K., C. Whitehurst, M. L. Pantelides and J. V. Moore (1995) Interstitial photodynamic therapy in the canine prostate. *Br. J. Urol.* **80**:898-902.
14. Selman S. H., R. W. Keck and J. A. Hampton (1996) Transperineal photodynamic ablation of the canine prostate. *J. Urol.* **156**:258-260.
15. Selman S. H., D. Albrecht, R. W. Keck, P. Brennan and S. Kondo (2001) Studies of Tin ethyl etiopurpurin photodynamic therapy of the canine prostate. *J. Urol.* **165**:1795-1801.
16. Chang S., G. A. Buonaccorsi, A. J. MacRobert and S. G. Bown (1997) Interstitial photodynamic therapy in the canine prostate with disulfonated aluminum phthalocyanine and 5-aminolevulinic acid-induced protoporphyrin IX. *The Prostate* **32**:89-98.
17. Chang S., G. Buonaccorsi, A. MacRobert and S. G. Bown (1996) Interstitial and transurethral photodynamic therapy of the canine prostate using meso-tetra-(m-hydroxyphenyl) chlorin. *Int. J. Cancer* **67**:555-562.
18. Hsi R. A., A. Kapatkin, J. Strandberg, T. Zhu, T. Vulcan, M. Solonenko, C. Rodriguez, J. Chang, M. Saunders, N. Mason and S. Hahn (2001) Photodynamic therapy in the canine prostate using motexafin lutetium. *Clin. Cancer Res.* **7**:6651-660.
19. Sheeham D. C. and B. B. Hrapchak (1987) *Theory and Practice of Histotechnology*, pp. 196-197.
20. Windahl T, S. O. Andersson and L. Lofgren (1990) Photodynamic therapy of localized prostatic cancer (letter). *Lancet* **336**: 1139.
21. Whitehurst C, M. L. Pantelides, J. V. Moore, P. J. Brooman and N. J. Blacklock. (1994) *In vivo* laser light distribution in human prostatic carcinoma. *J. Urol.* **151**:1411-1415.
22. Nathan T. R., D. E. Whitelaw, S. C. Chang, W. R. Lees, P. M. Ripley, H. Payne, L. Jones, M. C. Parkinson, M. Emberton, A. R. Gillams, A. R. Mundy and S. G. Bown. (2002) Photodynamic therapy for prostate cancer recurrence after radiotherapy: a phase I study. *J. Urol.* **168**:1427-1432.

23. Zilberstein J., S. Schreiber, M.C. Bloemers, P. Bendel, M. Neeman, E. Schechtman, F. Kohen, A. Scherz and Y. Salomon (2001) Anti vascular treatment of solid melanoma tumors with bacteriochlorophyll-serine-based photodynamic therapy. *Photochem. Photobiol.* **73**:257-263.
24. Bourre L., S. Thibaut, A. Briffaud, N. Rousset, S. Eleouet, Y. Lajat, and T. Patrice (2002) Indirect detection of photosensitizer *ex vivo*. *J Photochem Photobiol B.* **67**:23-31.

* zheng_huang@msn.com; tel: 303-3204061; fax: 303-3206018