

## The posterior parietal cortex in recognition memory: A neuropsychological study

Sharon Haramati<sup>a</sup>, Nachum Soroker<sup>b</sup>, Yadin Dudai<sup>a</sup>, Daniel A. Levy<sup>a,c,\*</sup>

<sup>a</sup> Department of Neurobiology, Weizmann Institute of Science, P.O. Box 26, Rehovot 76100, Israel

<sup>b</sup> Lowenstein Rehabilitation Hospital, Raanana, Israel, and Sackler Faculty of Medicine, Tel Aviv University, Tel Aviv, Israel

<sup>c</sup> Leslie and Susan Gonda (Goldschmied) Multidisciplinary Brain Research Center, Bar-Ilan University, Ramat-Gan, Israel

Received 13 February 2007; received in revised form 11 November 2007; accepted 15 November 2007

Available online 21 February 2008

### Abstract

Several recent functional neuroimaging studies have reported robust bilateral activation (L > R) in lateral posterior parietal cortex and precuneus during recognition memory retrieval tasks. It has not yet been determined what cognitive processes are represented by those activations. In order to examine whether parietal lobe-based processes are necessary for basic episodic recognition abilities, we tested a group of 17 first-incident CVA patients whose cortical damage included (but was not limited to) extensive unilateral posterior parietal lesions. These patients performed a series of tasks that yielded parietal activations in previous fMRI studies: yes/no recognition judgments on visual words and on colored object pictures and identifiable environmental sounds. We found that patients with left hemisphere lesions were not impaired compared to controls in any of the tasks. Patients with right hemisphere lesions were not significantly impaired in memory for visual words, but were impaired in recognition of object pictures and sounds. Two lesion–behavior analyses – area-based correlations and voxel-based lesion symptom mapping (VLSM) – indicate that these impairments resulted from extra-parietal damage, specifically to frontal and lateral temporal areas. These findings suggest that extensive parietal damage does not impair recognition performance. We suggest that parietal activations recorded during recognition memory tasks might reflect peri-retrieval processes, such as the storage of retrieved memoranda in a working memory buffer for further cognitive processing.

© 2007 Published by Elsevier Ltd.

**Keywords:** Memory; Parietal; Stroke; Recognition; Lesion study; CVA; Familiarity

The posterior parietal cortex (PPC) does not feature in standard accounts of brain substrates of the encoding, consolidation, or retrieval of long-term, declarative memory (Squire, Stark, & Clark, 2004). Nevertheless, in recent years a growing body of evidence has accumulated suggesting a parietal role in long-term memory processes. Event-related potentials (ERP) studies of brain activity during the retrieval phase of recognition memory tasks have reported left-lateralized positivity recorded at temporo-parietal sites, in the interval between 400 and 800 ms post stimulus onset, greater for correctly recognized words than for correctly rejected new words, and therefore sometimes called the “retrieval success effect” (Rugg, 1995). This ERP component has also been called the “parietal old/new effect” (e.g., Maratos,

Allan, & Rugg, 2000) or the “episodic memory (EM) effect” (e.g., Friedman & Johnson, 2000).

At first, this effect was believed to reflect memory-related activations of the medial temporal lobe (MTL) (Rugg, Schloerscheidt, Doyle, Cox, & Patching, 1996), which was then known on the basis of lesion studies to be differentially implicated in memory for words (affected more by left MTL lesions) and pictures (affected more by right MTL lesions; Milner, 1972). Schloerscheidt and Rugg (1997) tested this hypothesis by examining the old/new effect for pictures, which unlike the effect of words initially employed as stimuli was expected to have a more bilateral distribution. Contrary to this prediction, the parietal old/new effect was left-lateralized whether elicited by words or pictures (Schloerscheidt & Rugg, 1997; for a different view, see Mecklinger, 1998). These data raised the possibility that the old/new effect, as recorded on the scalp over temporo-parietal areas, does not directly reflect MTL activations, but rather other activations that are episodic memory retrieval-related and generalized across material types.

\* Corresponding author at: Department of Neurobiology, The Weizmann Institute of Science, P.O. Box 26, Rehovot 76100, Israel. Tel.: +972 8 934 3711; fax: +972 8 934 4131.

E-mail address: daniel.levy@weizmann.ac.il (D.A. Levy).

Implementation of fMRI methods in the study of retrieval enabled higher spatial resolution for the examination of the aforementioned left parietal old/new effect. Such studies have consistently shown an old/new effect or “retrieval success effect” in the lateral and medial parietal cortex, as well as in anterior dorsal and ventral prefrontal cortex and, less consistently, the medial temporal lobe (reviewed by Rugg & Henson, 2002). These findings add weight to the hypothesis that the observed ERP scalp distribution is generated in the immediately underlying parietal cortex, and it is tempting to assume that the effects observed with the two methods are neuroanatomically and functionally equivalent (Rugg, 2004). However, even if such memory-related activations are found in parietal cortex, it remains unclear what memory processes they might reflect. Possibilities include pre-retrieval attentional cognitive processes, actual retrieval of information (“ecphory”; Tulving, 1983), or post-retrieval utilization of retrieved information, among many others (Wagner, Shannon, Kahn, & Buckner, 2005).

ERP and fMRI old/new effects or “retrieval success effects” in PPC are not readily reconciled with traditional theories of PPC function that emphasize processes associated with spatial attention and motor intention. This raises the possibility that either spatial or motor processing differences confounded retrieval task designs for which the retrieval success effect was observed, so that the effect might not be directly related to mnemonic processes. In a series of three fMRI experiments, Shannon and Buckner (2004) addressed these issues. In the first experiment, they showed that the retrieval success effect occurs bilaterally, not only for visual stimuli (object pictures), but also for binaurally presented sounds, which do not require focus of visuospatial attention. They concluded that this effect is independent of cue modality and probably does not reflect pure visuospatial attention-related cognitive processes. In a second experiment, they addressed the argument that activity in these regions reflects response-related motor intention through manipulations of response procedures, and found that the old/new effect remains as is, whether the participant were instructed to respond only to old stimuli, only to new stimuli, or to respond both to old and new stimuli. In a third experiment, they showed stronger parietal activations for deeply encoded words (i.e., those studied in an encoding task requiring relating to the semantic features of the words) than for words that were subject to shallow encoding (on which orthographic judgments were made at study). Since that distinction is widely reported to affect retrieval, the implication is that the differential activation represents a mnemonic effect (Shannon & Buckner, 2004).

This study and others (reviewed by Wagner et al., 2005) appear to provide support for the contention that the parietal lobes play an integral role in memory processes, even for simple recognition tasks. More recently, it has been reported that in the absence of task, stimuli, or explicit mnemonic demands, robust correlations were observed between fMRI-assessed activity in the hippocampal formation and several parietal regions (including precuneus, posterior cingulate, retrosplenial cortex, and bilateral inferior parietal lobule). This was interpreted as supporting the mnemonic role of those parietal areas (Vincent et al., 2006). Nevertheless, EEG and fMRI provide only indirect

evidence for the neuroanatomical substrates of memory, because they can only reveal correlations between performance and activations, but not the necessity of such regions for the processes in question (Müller & Knight, 2006). While indirect evidence continues to accumulate for parietal involvement in recognition memory, direct evidence seems to paint quite a different picture. The vast majority of humans who have lesions to posterior lateral parietal sites (due to stroke, trauma or disease) do not seem to suffer from amnesia (in contrast to a few case studies of “retrosplenial amnesia”, in which medial parietal areas are affected, e.g. Saito, Kimura, Minematsu, Shiraiishi, & Nakajima, 2003; Valenstein et al., 1987; Yasuda, Watanabe, Tanaka, Tadashi, & Akiguchi, 1997). Furthermore, Rossi et al. (2006) recently reported applying repetitive transcranial magnetic stimulation (rTMS) to interfere with left or right parietal regions during encoding or retrieval stages of a recognition memory task. In the lower intensity condition, they found no significant reduction in performance relative to baseline, and at the higher intensity found only a generalized impairment that did not distinguish between application of rTMS to parietal areas and sham application. The authors conclude that the posterior parietal areas examined are not essential for recognition memory, and suggest that parietal activations observed in other studies could be due to additional brain processes that are simply associated with, but are not crucial for, the memory challenge (Rossi et al., 2006).

The neuropsychological study reported here was conducted with the aim of further clarifying the issue of parietal contributions to long-term memory. We tested recognition memory performance of right and left hemisphere cerebro-vascular accident (CVA) patients whose lesions encompassed posterior parietal areas, on tasks that elicited activation in PPC areas in fMRI studies (Shannon & Buckner, 2004), and thereby assessed the PPC contributions to those types of memory tasks. We found that patients with left hemisphere lesions were not impaired compared to controls in any of the tasks. Patients with right hemisphere lesions were not significantly impaired in memory for visual words, but were impaired in recognition of object pictures and sounds. Two types of analysis, namely, lesion–behavior correlations and voxel-based lesion symptom mapping (VLSM) analysis did not reveal significant parietal contributions to those recognition memory impairments, but rather implied that these impairments resulted from damage outside the parietal lobes.

## 1. Methods

### 1.1. Participants

#### 1.1.1. Patients

20 first incident CVA (cerebro-vascular accident: ischemic or hemorrhagic) patients between the ages of 26–82 participated in this study. The patients were recruited during their hospitalization in Loewenstein Rehabilitation Hospital, Raanana, Israel. All patients provided informed consent to participate in the study, which was performed using a protocol approved by the human subjects research committee of the Loewenstein Rehabilitation Hospital, in accordance with the ethical standards laid down in the 1964 Declaration of Helsinki. Patients were included in the study only if they did not suffer from psychiatric or prior neurological disorders, did not use psychotropic drugs, and their language and cognitive status enabled full comprehension of the task requirements. For three patients (1 RHD: TC; 2 LHD: MM, YE), although initial radiological assess-

Table 1  
Demographic and clinical data

Patient	Age/sex	Hand	Edu	Lesion side	Lesion type	TAO	MI	SI	VFD	Neglect	Aphasia
HD	27/F	R	13	L	CVST-H	14.6	++	±	–	–	–
GS	32/F	R	12	L	AVM-H	4.1	–	±	–	+	–
MM**	33/F	R	16	L	CVST-H	4.6	–	–	–	–	–
MK	43/M	R	12	L	H	12.4	+	±	–	–	–
YE**	77/F	R	13	L	I	12.3	+	–	–	–	TM
NS	62/M	R	8	L	H	14	–	–	–	–	+
YM	57/M	R	10	L	H	3.0	+	±	–	–	–
BT	52/F	R	12	L	I	16	++	+	–	–	+
AM	72/M	R	12	R	I/H	3.3	+	±/e	–/e	+	–
GD	29/F	R	17	R	I	4.4	+	±	–/e	+	–
GSa	60/F	R	11	R	I	5	++	+	–/e	+	–
OA	76/M	R	16	R	I	6.6	NA	NA	NA	+	–
RE	57/M	L	15	R	I	6.3	++	±	–/e	–	–
SA	63/F	L	12	R	H	3	+	+/e	–	–	–
SO	26/F	L	12	R	AVM-H	5	+	±	–	–	–
SS	40/F	R	14	R	H	10.4	++	+/e	–/e	+	–
TC**	82/F	R	15	R	NA	5.4	NA	NA	NA	NA	–
TH	61/F	L	17	R	I	12.8	++	++	–/e	+	–
YD	62/M	R	8	R	I	3.6	+	±/e	–/e	–	–
ZO	66/F	R	9	R	I	13.3	+	±	–/e	+	–

Hand, handedness; Edu, formal education years; H, hemorrhagic stroke; I, ischemic stroke; I/H, ischemic with hemorrhagic transformation; CVST, cerebral venous sinus thrombosis; AVM, arterial venous malformation, TAO, time after onset (weeks); MI, motor impairment; SI, sensory impairment (–, no impairment; ±, non disabling impairment; +, mild impairment; ++, moderate/severe impairment); VFD, visual field defect (–, no; –/e, extinction upon bilateral simultaneous stimulation but no VFD), TM, transcortical motor. (\*\*) Excluded from behavioral analyses, only included in lesion–symptom analyses (see text).

ment had indicated parietal involvement, quantitative radiological analysis (see below) did not confirm posterior parietal lesions, so these patients were excluded from the behavioral analysis of patient vs. control memory performance. However, they were included in the lesion–behavior correlation and VLSM analyses (see below), providing additional data points for the detection of other cortical areas implicated in the performance of the tasks. Of the patients included in the behavioral analyses, 11 had right hemisphere damage (RHD), and of those, 8 were right-handed and 6 females. The RHD group mean age was 55.7 years (S.D. = 16.7), and they had 13.4 years of formal education (S.D. = 3.2). Six patients included in the behavioral analyses had left hemisphere damage (LHD); all of these were right-handed, and three were females, with an overall mean age of 45.7 years (S.D. = 14.2), and 11.2 years of education (S.D. = 1.8). Table 1 details the demographic and clinical data for each patient.

### 1.1.2. Controls

27 healthy individuals, aged 25–76 with no history of neurological or psychiatric disorders, served as control participants, in return for payment. They were matched to patients by sex, age and education separately for the LHD and RHD patient groups: 22 RHD-matched controls, 14 females, mean age 55.9 (S.D. = 14.0), years of education = 13.5 (S.D. = 2.7); 13 LHD-matched controls, 7 females, mean age 47.1 (S.D. = 15.0), years of education = 14.5 (S.D. = 2.4).

## 1.2. Behavioral procedures

We employed two recognition tasks with three types of memoranda, similar to the tasks employed by Shannon and Buckner (2004). See Fig. 1 for illustration.

### 1.2.1. Written words task

In the encoding phase, participants were shown 40 Hebrew words serially on a computer screen, and were instructed to read the word aloud and to make an abstract/concrete judgment for each word. This procedure was performed twice, with the words appearing in a different order each time. After a 15 min delay, participants performed a recognition memory test. They were then serially presented with a list of 80 words, of which 40 had been seen previously and 40 had not. Participants were instructed to indicate by key-press whether each word presented was old or new. At both encoding and test, each word appeared

centrally on the computer screen in white letters on a black background, until a response was made by the participant, followed by a blank screen for 1000 ms, and then a fixation cross for 500 ms preceding the appearance of the next word. Four practice trials preceded both encoding and test sections.

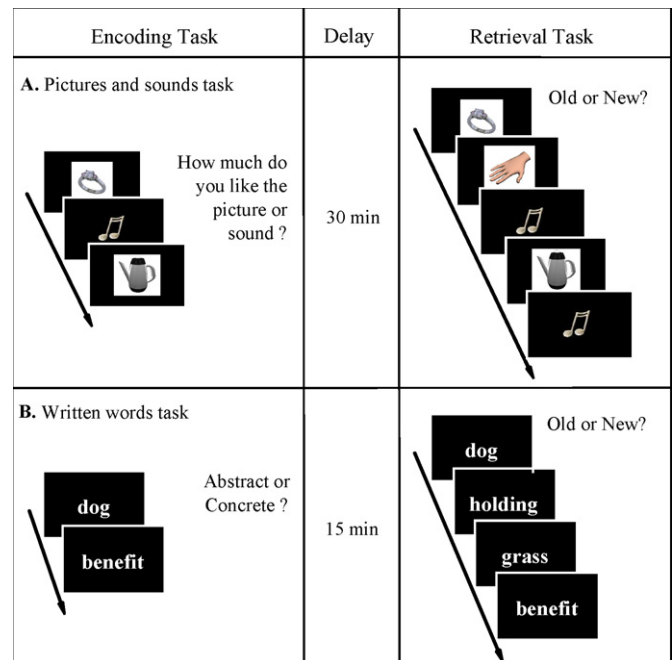


Fig. 1. Schematic portrayal of the encoding and retrieval tasks. (A) Pictures and sounds memory task. Encoding of colored images and natural sounds followed by a 30 min break and a retrieval test. (B) Memory task for written words. Encoding session followed by a 15 min break and a retrieval test. See text for details.

### 1.2.2. Picture/sound task

Participants were presented with intermixed stimuli (30 pictures and 20 sounds), one at a time, for encoding by key-press rating on a scale of 1–5 of how much they liked the stimulus. Pictures were presented on a computer screen, appearing centrally as a colored image in a white square on a black screen for 1500 ms. The pictures portrayed common objects such as tools, animals, musical instruments, and foods. Sounds were of varied duration, but all were between 1500 and 2000 ms. These included natural sounds (e.g., dog bark, cat meow) and mechanical sounds (e.g., jet engine, breaking glass). They were presented through headphones while a small light-blue note sign appeared centrally on the black screen. Each stimulus was preceded by a fixation cross for 500 ms and followed by the instruction “rate”. Participants could respond to the stimulus only after the instruction appeared on the screen. This procedure was performed twice, with the stimuli appearing in a different order each time. After a 30 min delay, a recognition test was administered. Participants were presented with the 50 previously rated stimuli (old) and 50 previously unrepresented stimuli (new), intermixed, and were instructed to indicate by key-press if the stimulus was old or new. The question “old or new?” appeared on screen immediately upon the offset of the stimulus. Response time was unlimited. The next test stimulus was presented immediately after response. Prior to the encoding task, seven unrelated sounds were presented to the patient for volume adjustment, followed by two practice sounds and two practice pictures. Prior to the test task, four practice stimuli were presented to make sure that the patients understood and performed the task appropriately.

In both tasks, all stimuli appeared equiprobably as targets (old) and foils (new), by counterbalancing across participants. In addition, we counterbalanced across participants the order of the text and picture/sound tasks. The participants were aware that they were participating in a memory study, but were not directly instructed to memorize any items, nor were they told what the exact structure of the test task would be.

All visual stimuli were presented on the (12.1 in., TFT display) screen of an IBM ThinkPad X40 laptop computer, running Presentation® software (Version 9.70, Neurobehavioral Systems Inc., Albany, CA. [www.neurobs.com](http://www.neurobs.com)). Sound stimuli were presented through headphones (Aiwa HP-CRT21M) using the same computer. Responses were recorded by the Presentation® software while participants responded using the computer’s keyboard covered by a mask exposing only the relevant response keys.

Visual and auditory stimuli were collected from various open web databases. Lists of Hebrew words were constructed to match the English word lists employed by Shannon and Buckner (2004), with target and foil lists balanced for number of letters and syllables, frequency and concreteness, using the databases published by Henik, Rubinstein, and Anaki (2005).

### 1.2.3. WMS-III

We tested patients’ general memory skills by using the primary Wechsler Memory Scale-III subtests: Logical Memory (immediate and delayed (I & D) memory for two short stories), Faces (I & D recognition of novel faces), Verbal Paired Associates (I & D memory for pairs of non-related words), Family Pictures (I & D memory for four pictorial scenes), Letter–Number Sequencing (testing working memory abilities, both retention and manipulation of a sequence of letters and numbers) and Spatial Span (a test of spatial working memory for a tapping sequence on 3D Cubes). Verbal materials were presented in Hebrew translation. Patients were graded according to the WMS-III scoring criteria and published norms (Wechsler, 1997). It should be noted that the Hebrew translation of the WMS-III has not been independently normed, and scaled scores reported here, based on equivalent U.S. norms, should be considered accordingly. Three LHD patients (NS, MY, and TB) were unable to complete the WMS-III test because of expressive language difficulties.

### 1.3. Behavioral data analysis

Discrimination scores ( $d'$ ) and bias estimates (beta ratios) are reported separately for Sounds, Pictures, and Words tasks, for each patient group and their controls. For test scores of 100% hits, a corrected score was substituted using the formula of  $1-1/2n$  ( $n$ =the number of test items), and for 0% false alarms a corrected score was substituted using the formula of  $1/2n$ . For patients, the percentage of corrected observations was Sounds, 2.0%, Pictures, 12.8%, and Words, 2.9%. For controls, the percentage of corrected observations was Sounds, 3.8%, Pictures, 20.5%, and Words, 7.1%. The relatively large number of corrections in the Pictures test reflects a tendency towards ceiling performance (see below). Beta ratios of under 1.0 are understood as reflecting a tendency towards false alarms, with higher betas reflecting a more conservative response criterion. We did not analyze reaction time data because most patients had various motor difficulties resulting from their CVA-induced damage. For group behavioral statistical analysis, we used one-tailed Mann–Whitney (Wilcoxon) two-sample tests with normal approximation.

### 1.4. Lesion analysis

For lesion analysis, we used follow-up computerized tomography (CT) scans, performed during the rehabilitation period, dating on average 37 days post-stroke onset. Lesion analyses were performed with the Analysis of Brain Lesions (ABLE) module implemented in Medx software (Medical-Numerics, Sterling, VA, USA). ABLe characterizes brain lesions in magnetic resonance

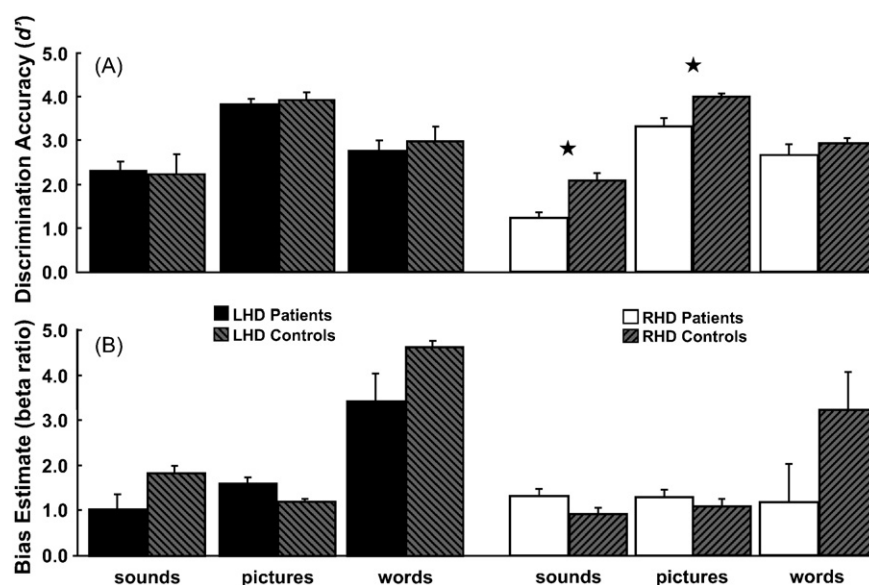


Fig. 2. Group behavioral results. (A) Mean ( $\pm$ S.E.M.) discrimination accuracy scores ( $d'$ ) and (B) bias estimates (beta ratios) for the three material type tasks, in right and left hemisphere damage patients and respective matched controls. (\*) Indicates difference significant at level of  $p < 0.01$ .

imaging (MRI) and computerized tomography (CT) scans of the adult human brain by spatially normalizing the lesioned brain into Talairach space using the Montreal Neurological Institute template brain. It reports anatomical structures in the normalized brain by using an interface to the Talairach Daemon (San Antonio, Texas) or the Automated Anatomical Labeling (AAL) atlas (Tzourio-Mazoyer et al., 2002), and quantifies the amount of lesioned tissue in those standard structures (as previously described in Mah, Arnold, & Grafman, 2004).

Lesions were manually outlined on the digitized CTs using the MEDx software. One patient's CT could not reach automatic normalization of satisfactory quality and therefore the lesions were manually drawn onto a rescaled MNI template and were further processed as all the other cases. Registration accuracy of the scans to the Montreal Neurological Institute template ranged from 92.7 to 95.4% with a mean of 94.2% (S.D. = 0.93).

### 1.5. Lesion–behavior correlations

Using the output of the ABL module, multiple Pearson's correlations were performed across subjects, correlating the percentage of lesion in AAL determined brain structures (AAL labels) and their recognition performance ( $d'$  scores) for the three stimulus types (sounds, pictures, words). Only structures with over 5% lesion in at least four RHD patients or at least two LHD patients were included in the analysis. We report all areas for which lesion–behavioral correlations were significant up to  $p < 0.1$ , to insure detection of parietal (or other) areas possibly implicated in recognition impairment, even at a lenient criterion.

### 1.6. Voxel-based lesion symptom mapping (VLSM)

VLSM methodology (described by Bates et al., 2003) enables the identification of brain regions that may affect behavior, and was recently implemented in ABL. VLSM analyzes the brain and behavior in a voxel-by-voxel manner. For each voxel, the software determines which patients have and which are lacking a lesion to that voxel (lesions must be normalized to a common space prior to this analysis). Then, a  $t$ -test is computed between the behavioral results of these two groups of patients (with potentially different groups for each voxel). The output of this procedure is a map in which each voxel is assigned a  $t$ -value. The minimal group size for analysis was set to three patients. Only voxel clusters of more than 50 contiguous voxels, for which the  $t$ -test remained significant after Bonferroni correction, are presented. Significant clusters were then compared to AAL atlas, and all AAL structures occupying more than 5% of the significant clustered voxels are reported.

## 2. Results

### 2.1. Behavioral analysis

#### 2.1.1. Recognition memory

Data was analyzed separately for 11 RHD and 6 LHD patients with confirmed posterior parietal lesions, each with their matched control groups. One RHD patient (AM) and three controls were excluded from the Pictures analysis, and one RHD patient (AM) from the Words analysis, as outliers ( $-3$  S.D.).

Fig. 2A portrays discrimination scores ( $d'$ ) of patients and controls for the three material types. Recognition performance of LHD patients did not significantly differ from that of matched controls at any of the tasks (Pictures, Sounds or Words, all  $ps > 0.27$ ). RHD patients were not significantly impaired in recognition of Words ( $Z = -1.26$ ,  $p > 0.21$ ). Impairments were found in recognition memory for Pictures,  $Z = -2.98$ ,  $p < 0.01$ , and for Sounds,  $Z = -3.06$ ,  $p < 0.01$ ).

The main group of patients included in the above behavioral analysis all had extensive lateral parietal damage. Medial parietal damage was rarer; however, three LHD patients did have notable

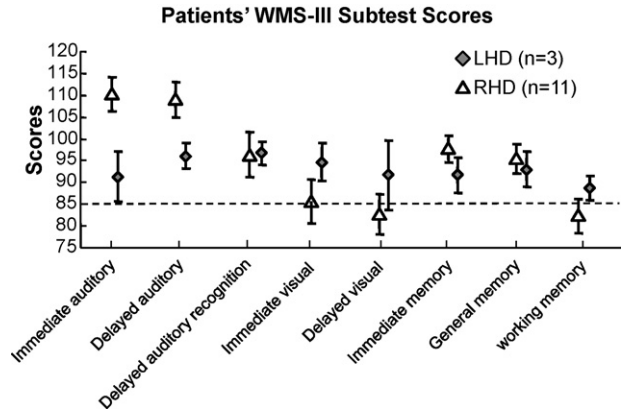


Fig. 3. WMS-III group results. Mean ( $\pm$ S.E.M.) scaled scores of the RHD (triangles) and LHD (diamonds) patient groups in the various WMS-III subsets. Dotted line indicates one S.D. from population mean scores.

damage to the precuneus (GS, 19.4%; HD, 19.8%; MK, 21.8%). We separately compared their performance with six matched controls (age, patients = 34.0 years, controls = 34.8 years; education, patients = 12.3 years, controls = 13.0 years). There were no significant differences in the mean  $d'$  scores of these groups (Sounds, patients  $d' = 3.19$ , controls  $d' = 2.61$ ; Pictures, patients  $d' = 3.95$ , controls  $d' = 3.86$ ; Words, patients  $d' = 2.67$ , controls  $d' = 3.31$ ; all  $ps > 0.20$ ).

Beta ratios are presented in Fig. 2B. For none of the stimulus types did any patient or control groups exhibit a tendency to false alarm responding (beta ratio  $< 1.0$ ). Furthermore, no significant group differences in beta ratios were found between either LHD or RHD patients and their controls (all  $ps > 0.27$ ). However, since the non-parametric tests employed might have failed to capture relevant group differences (notably in the case of the Words task), and to explore possible brain substrates of the tendency to false alarm responding in individual patients, we subjected the beta ratios to lesion–symptom correlations (see below).

#### 2.1.2. WMS-III

Fig. 3 shows mean ( $\pm$ S.E.M.) WMS-III scaled scores for 11 RHD and 3 LHD patients with confirmed posterior parietal damage (3 additional LHD patients could not complete the WMS-III testing because of language impairments). LHD patients had within-norms scores for all memory types. RHD patients had better auditory than visual memory scores: higher than norm auditory memory (both immediate and delayed) and marginally worse visual memory scores (immediate and delayed). As a result, in the summary immediate and general (i.e., delayed) memory scores, the RHD patient group achieved within-norm scores (as did LHD patients). In contrast, the RHD patients performed marginally worse than norm in the working memory tasks, and the LHD patients similarly performed more poorly on working memory than on other memory measures.

### 2.2. Lesion analysis and lesion–behavior correlations

In order to identify brain areas that might be functionally significant for memory performance in these tasks, we




Fig. 4. (A) Lesions of each patient marked on arrays of 11 standard Damasio templates. (B) Lesion overlap of all the patients superimposed on Damasio templates. Colors represent the number of overlapping lesions at that region. Displays follow neurological conventions, i.e., RH displayed on left side and LH on right side.

used quantitative methods to characterize each patient's lesions and related that information to their recognition memory data. Fig. 4A shows the extent of each patient's lesions using 11 representative axial CT slices, in accordance with the method of Damasio and Damasio (1989) and Fig. 4B shows an overlap of all lesions of RHD and LHD patients. Not all brain areas are covered by lesions of these patients. Therefore, any inferences from this lesion analysis are confined to affected regions, and cannot extend to other regions that might be important for the measured behaviors.

Lateral posterior parietal regions of interest, including superior parietal lobule (SPL), inferior parietal lobule (IPL; additional to SMG and AG, as defined in the AAL atlas), supramarginal gyrus (SMG) and angular gyrus (AG) are markedly involved in most patients' lesions. Specifically, for the 11 RHD patients and 6 LHD patients who were included in the behavioral comparisons with the control groups, mean lesion extents were: *SPL*: RHD 15%, LHD 18%; *IPL*: RHD 30%, LHD 32%; *SMG*, RHD 41%, LHD 23%; *AG*, RHD 27%, LHD 37%. In contrast, medial parietal regions of interest such as the precuneus appear to be affected only in some of the LHD patients (as noted above); therefore, no conclusions can be drawn regarding this region in the RHD lesion analysis. In addition, size and locations of lesions differ markedly between right and left hemisphere CVA patients (as do their demographic factors), so one must be cautious in any attempt to compare results from these two groups. Total lesion volumes (in individual patients) ranged from 6 to 245 cm<sup>3</sup> (mean = 81 cm<sup>3</sup>, S.D. = 62 cm<sup>3</sup>). In RHD patients, lesion volumes ranged from 10 to 245 cm<sup>3</sup> (mean = 92 cm<sup>3</sup>, S.D. = 67 cm<sup>3</sup>), and in LHD patients lesion volumes ranged from 6 to 112 cm<sup>3</sup> (mean = 61 cm<sup>3</sup>, S.D. = 42 cm<sup>3</sup>).

All lesions were registered onto standard MNI templates, using the ABLe module implemented in MEDx software (see methods). [Supplementary Table 1 depicts the percent of each patient's lesion in each AAL atlas brain area.] These percentages were then used to perform correlations between percent lesion in each AAL brain area and recognition performance. Table 2 displays AAL structures in which damage was negatively correlated with  $d'$  or beta ratio at a level of significance of up to  $p < 0.1$ .

In the RHD group, frontal and temporal lobe areas and the insula were implicated in discrimination impairment (i.e., lower  $d'$  scores) on the Sounds task; frontal lobe areas and the putamen were implicated for the Pictures task. No lesion-impairment correlations were found for the Words task. Though the LHD group was unimpaired relative to controls on all tasks, correlations revealed that within the group, damage in the following areas were associated with poorer performance: Words task: medial and lateral occipital areas, the posterior cingulum, and the angular gyrus. No correlations were found for the Sounds or Pictures tasks. Regarding bias estimates (beta ratios), for RHD patients, in the Sounds and Words tasks, lower beta ratios (i.e., greater tendency to false alarm responding) were correlated with the extent of damage to frontal cortex. No correlations were found for Pictures tasks. For LHD patients, lower beta ratios in the Words task were correlated with the extent of damage to the supplementary motor area, mid-cingulum, supramarginal gyrus, and postcen-

tral gyrus. No correlations were found for Sounds or Pictures tasks.

### 2.3. VLSM analysis

Voxel-based lesion symptom mapping (VLSM; Bates et al., 2003) was computed only for the RHD group, because the total number of shared voxels in the LHD group was very small. Fig. 5A displays representative slices from a lesion overlay that illustrates the volume on which VLSM analysis could be computed (lesion overlap of at least three patients). Fig. 5B illustrates representative slices from the VLSM  $t$ -maps computed for recognition behavior ( $d'$ , beta ratio) in the three tasks (Pictures, Sounds and Words). Clusters of more than 50 voxels showing significant  $t$ -values (after Bonferroni correction) are shown.

Discrimination accuracy ( $d'$ ) mapped as follows: Poorer recognition of pictures was associated with damage to middle and superior temporal gyri and superior temporal pole. Poorer

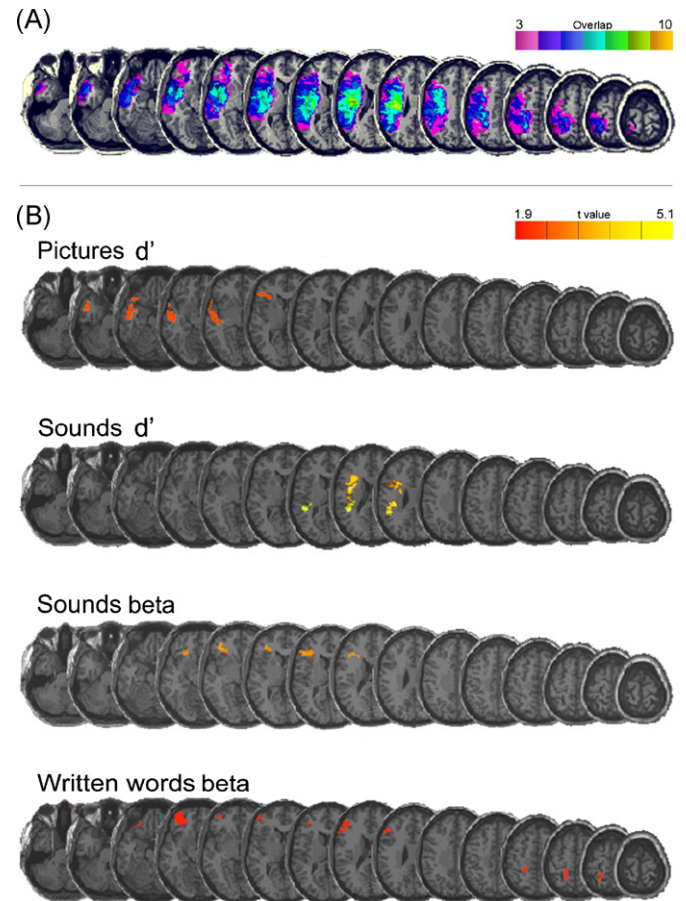


Fig. 5. Voxel-based Lesion Symptom Mapping (VLSM). (A) Representative slices from overlay of lesions from all RHD patients (min. lesion overlap = 3). This indicates the areas upon which VLSM was computed. (B) Representative slices from VLSM maps computed for behavioral performance of the RHD patients in the tasks for which significantly lower  $d'$  or beta ratios were found in patients vs. controls, overlaid on an MNI template brain. Colored pixels represent clusters larger than 50 contiguous voxels of significant  $t$ -values (after Bonferroni correction). Every 4th slice is presented from  $Z = -36$  mm to  $Z = +78$  mm in MNI space. Slice thickness = 2 mm. For identification of areas, see text. Displays follow neurological conventions, i.e., RH displayed on left side.

Table 2  
Structures in which lesion volumes of AAL-defined regions significantly correlated with behavioral measures

RHD patients			
Task	AAL label	Pearson's <i>r</i>	<i>p</i> -Value
Structure lesions inversely correlated with discrimination accuracy ( <i>d'</i> )			
Sounds	Inferior frontal gyrus – opercular part	−0.67	0.02
	Inferior frontal gyrus – orbital part	−0.52	0.09
	Inferior frontal gyrus – triangular part	−0.59	0.04
	Rolandic operculum	−0.75	0.01
	Insula	−0.80	0.01
	Heschl's gyrus	−0.74	0.01
	Superior temporal gyrus	−0.65	0.02
	Superior temporal	−0.58	0.05
Pictures	Inferior frontal gyrus – orbital part	−0.51	0.07
	Putamen	−0.65	0.02
Words	–	–	–
Structure lesions inversely correlated with bias (beta ratio)			
Sounds	Inferior frontal gyrus – orbital part	−0.57	0.05
	Gyrus Rectus	−0.56	0.06
Pictures	–	–	–
Words	Middle frontal gyrus – orbital part	−0.53	0.08
LHD patients			
Task	AAL label	Pearson's <i>r</i>	<i>p</i> -Value
Structure lesions inversely correlated with discrimination accuracy ( <i>d'</i> )			
Sounds	–	–	–
Pictures	–	–	–
	–	–	–
Words	Posterior cingulate	−0.67	0.07
	Superior occipital	−0.76	0.03
	Middle occipital	−0.68	0.07
	Cuneus	−0.68	0.06
	Angular gyrus	−0.71	0.05
Structure lesions inversely correlated with bias (beta ratio)			
Sounds	–	–	–
Pictures	–	–	–
	–	–	–
Words	Middle cingulate	−0.64	0.09
	Supplementary motor area	−0.67	0.07
	Postcentral gyrus	−0.64	0.09
	Supramarginal gyrus	−0.65	0.08

recognition of sounds was associated with damage to inferior frontal gyrus (triangular and opercular parts), the Rolandic operculum, and to a cluster that included contiguous areas of superior temporal, angular, and supramarginal gyri. No areas were significantly associated with discrimination deficits for words; the only major area approaching significance was inferior temporal gyrus. Regarding bias estimates (beta ratios), damage in middle frontal gyrus and inferior frontal gyrus (triangular and orbital parts) was associated with a greater tendency to false alarm responding in the Sounds task. Damage to several frontal lobe areas (superior frontal gyrus, orbital part; middle frontal gyrus; middle frontal gyrus, orbital part; inferior frontal gyrus, triangular part; inferior frontal gyrus, orbital part) and to the postcentral gyrus (with a small contiguous portion of superior parietal lobule) was associated with a greater tendency to false alarm responding in the Words tasks. In no areas was damage so implicated for the Pictures task. Notably, for both *d'* and beta

measures, additional voxel clusters in which damage was associated with poorer performance but did not survive Bonferroni correction were found in frontal and temporal areas, but not in posterior parietal areas.

### 3. Discussion

Posterior parietal fMRI activations engendered by recognition memory retrieval tasks have been reported for different stimulus types (Wagner et al., 2005). If these activations reflect an essential aspect of the retrieval process, we would expect that lesions in those parietal areas would yield recognition impairments. However, the recognition performance of CVA patients with damage including parietal regions examined in this study did not corroborate the essential role of posterior parietal cortex in recognition. Notably, LHD patients were not at all impaired in recognition memory when compared to

healthy controls. RHD patients as a group were impaired in their memory for pictures and sounds, but not for words. However, anatomical analyses cast doubt on the posterior parietal basis of those impairments. Patient lesions were generally not confined to parietal regions, and we therefore conducted detailed behavioral–neuroanatomical correlations to identify lesion sites affecting recognition performance. We employed two different analytic methods: (1) correlation between the extent of lesions in anatomical regions as commonly parcellated (in this case, following the AAL atlas) and performance (Soroker et al., 2005), and (2) voxel-based lesion symptom mapping (VLSM; Bates et al., 2003), which has the benefit of not requiring any assumptions regarding boundaries of brain structures. The deficits exhibited by RHD patients might have been caused by encoding as well as retrieval failures, and brain damage might have affected either of these stages (as well as storage deficits, i.e., more rapid forgetting). For RHD patients, area-based correlations and VLSM identified frontal and temporal lobe as well as neostriatal areas in which damage was associated with poorer recognition discrimination accuracy. In contrast, damage to posterior parietal regions was generally not found to be correlated with impaired recognition performance, neither in discrimination accuracy ( $d'$ ) nor in bias estimates (beta ratios). One exception was the emergence in VLSM of a cluster of voxels occupying small volumes in angular and supramarginal gyri, damage to which was associated with poorer  $d'$  in the sounds task. However, those voxels were contiguous with a group of implicated voxels located in the superior temporal gyrus. Since this finding was specific to the sounds task, it is likely that auditory processing difficulties caused by that superior temporal area damage affected memory performance, and that those parietal areas were marked as being implicated in the performance deficit because of their contiguity to the temporal area.

LHD patients as a group were not impaired relative to their matched controls. However, we attempted to determine whether within this group any areas could be identified as being implicated with poorer memory performance. Due to small areas overlapping among patients in this group, VLSM analysis could not be performed on LHD data. Area-based correlations did not identify structures damage of which might have affected picture task performance, but marked lateral and medial occipital regions in which damage was correlated with poorer discrimination accuracy in the words task. Furthermore, of the regions of interest to the present study, damage to the angular gyrus was correlated with poorer words task performance, and damage in the supramarginal gyrus (among other areas) was associated with a less stringent response criterion (beta ratio). It is not surprising that damage in left hemisphere supramarginal or angular gyri would affect performance in the Words task, as they have been implicated in the processing of verbal material in general. For example, Chou et al. (2006) reported left IPL fMRI activations related to semantic association judgment. Therefore, it is possible that the correlation between poorer words task performance and left angular gyrus lesions stem from basic language processing affecting encoding and retrieval, rather than mnemonic processes per se. It should be remembered, however, that the LHD patients were not in fact impaired relative to controls.

It is also important to note that the three LHD patients with damage to the precuneus, when separately compared to their matched controls, showed no memory impairment (though this finding should be treated with caution due to the small number of patients involved).

The absence of convincing evidence for a specifically parietal contribution to memory deficits, together with the fact that the same analysis succeeded in revealing widespread extra-parietal regions (frontal and lateral temporal cortices and neostriatum) significantly associated with such deficits, raises questions regarding the putative parietal contributions to basic recognition memory. The parietal old/new effect, described in ERP and fMRI studies, is indeed robust, being found in various contrasts and conditions, and across material types. Nonetheless, our study failed to find direct evidence for an effect of parietal lesions on recognition performance. Our findings are consistent with the lack of reports of memory impairments following lateral parietal lesions, and are reinforced by recently published work by Rossi et al. (2006) in which TMS to parietal sites (IPS), at encoding and retrieval, failed to specifically reduce recognition accuracy. All these factors lead us to the conclusion that parietal activations reported in electrophysiological and neuroimaging studies reflect peri-retrieval auxiliary processes that are not essential for recognition memory abilities.

A number of caveats regarding these results are in order:

- (1) Lesions in all patients participating in this study were unilateral. Activations reported in imaging and electrophysiological studies are bilateral (generally LH > RH), and inter-hemispheric compensation is always a possibility. We cannot therefore rule out the possibility that RH parietal lesions are compensated by homologous LH healthy tissue, and vice versa. Although the patients in this study were tested relatively soon after the precipitating lesions (mean 7.7 weeks after stroke onset), interhemispheric compensatory plasticity may obtain at by that time period (in neglect: Corbetta, Kincade, Lewis, Snyder, & Sapir, 2005; in aphasia: Saur et al., 2006). However, while compensation might ameliorate deficits, it seems unlikely to eliminate them completely (Müller & Knight, 2006). It is notable that unilateral (RH) retrosplenial damage was reported to cause visual and verbal memory impairments (Yasuda et al., 1997). Unilateral MTL lesions, while generally not leading to amnesia as severe as that caused by bilateral damage, often yield memory impairment (Baxendale, 1998; Spiers, Maguire, & Burgess, 2001). It is sometimes assumed that such unilateral lesions cause material-specific memory impairment, greater for verbal material after LH MTL damage and for visual material after RH MTL damage (e.g., Alessio et al., 2006). A meta-analysis of studies of the effects of unilateral temporal lobe resection in epilepsy patients confirmed that verbal mental abilities, as assessed by the Logical Memory subtest of the WMS, were found to be impaired following left temporal lobe resections; the effects of right temporal lobe resection were less clear-cut (Lee, Yip, & Jones-Gotman, 2002). However, careful assessment of memory abilities may reveal deficits in memory for verbal

materials after MTL damage in either hemisphere (Dobbins, Kroll, Tulving, Knight, & Gazzaniga, 1998). Furthermore, it is notable that in our study, lesions in LH parietal cortex (where retrieval-related activations are reported to be strongest; Wagner et al., 2005) were not found to cause any memory deficits.

- (2) Medial parietal regions of interest (precuneus and retrosplenial cortex) were affected in only a few LH patients. Though the latter did not exhibit any recognition impairment, conclusions regarding the contribution of such regions to recognition must remain tentative.
- (3) Several participants, both patients and controls, performed at ceiling in the test of picture recognition. Accordingly, this test might not have captured possible LH patient impairments.
- (4) As noted, we conducted testing for each patient as soon as possible after stabilization of edemas, to avoid effects of plasticity. LH patients were on average tested about 3 weeks after onset later than RH patients. It is possible that RH patients might have performed better if tested at the same time as LH patients.
- (5) The recognition tests employed in the current study as well as in the study of Shannon and Buckner (2004) do not discern between recognition judgments made on the basis of familiarity alone and those that are accompanied by recollection, i.e. stimulus-cued retrieval of contextual information. It is possible that such recollective processes might require parietal contributions.

What, then, may be said about memory processes by contrasting neurophysiological findings with the results reported herein? Wagner et al. (2005) suggested a number of hypothetical interpretations of parietal activations during recognition memory tasks, which bear re-examination in light of our findings.

- (1) *Attention to internal representations*: Memory judgments typically demand attentional shifts to internal representations, and attentional focus is one of the standard acknowledged functions of the PPC (Corbetta & Shulman, 2002). Notably for memory processes, there are clear anatomical connections between both medial and lateral parietal cortices and the MTL. For example, monkey IPL has been shown to have direct reciprocal projections to parahippocampal cortex (Lavenex, Suzuki, & Amaral, 2002; Suzuki & Amaral, 1994) and direct projections to hippocampus (Rockland & Van Hoesen, 1999). Therefore, Wagner and colleagues speculate that PPC regions might shift attention to, or maintain attention on, internally generated MTL-dependent mnemonic representations, and thereby enhance their processing to enable recognition memory judgments, much as spatial- and object-based attention enhances perceptual processing. Our results seem to speak against this interpretation. If such attentional shifts were prerequisite to successful retrieval, we would expect that PPC damage should cause memory-impairment (which it does not). An alternative is that PPC serves to focus attention on retrieved

information after retrieval (a notion related to option #3 below).

- (2) *Memory trace accumulator function*: Wagner and colleagues propose that recognition memory decisions might require parallel accumulation of evidence about the history of a stimulus, and that regions in lateral PPC might perform such computations on inputs from the MTL, contributing to decision processes concerning an item's mnemonic status. This option seems similarly unlikely in the face of the negative findings regarding memory deficits yielded by parietal lesions.
- (3) *Output buffer*: A third possibility is that PPC regions represent already-retrieved information in a form accessible to decision-making processes, serving a function analogous to Baddeley's working memory buffers (Baddeley, 2003). Similarly, in regard to medial parietal regions (which we were unable to investigate fully in the current study), Kobayashi and Amaral (2003) report that afferent connections to retrosplenial cortex are dominated by MTL projections. They therefore speculate that retrosplenial cortex acts as an interface zone between the working memory (executive) functions enabled by prefrontal cortex and the declarative memory functions subserved by the MTL.

This last possibility is not ruled out by the current results, and may represent a reasonable option for understanding the wide range of findings about parietal involvement in declarative memory processes. Under ecological conditions, recognition memory is rarely a goal in itself. Rather, we may use the familiarity signal to initiate a search of memory stores for more information about the recognized person, place, or object, and proceed to take actions based on such information. We probably need to keep the retrieved representations in working memory in order to enable assessment and use of such information. PPC has been consistently implicated in working memory processes in many neuropsychological and imaging studies (Müller & Knight, 2006; Wager & Smith, 2003). Together with prefrontal areas, it may form a network that enables 'working-with-(retrieved)-memory' (cf. Moscovitch & Winocur, 2002). Indeed, the working memory tests that we administered (as part of the WMS-III battery; Fig. 3, above) revealed that both LHD and RHD patient groups were relatively deficient in working memory performance. Such an interpretation may account for the finding that parietal activations may be higher in response to false alarms than to correct rejections (Wagner et al., 2005) – even a mistaken familiarity judgment may cause a stimulus to be held in working memory for the purpose of further memory exploration. Furthermore, since working memory and selective attention may be understood as forming two sides of the same cognitive coin (Desimone & Duncan, 1995), PPC involvement in buffering retrieved information and attending to it (as we suggested above) is a coherent possibility. Future studies, assessing the brain basis of working memory specifically for retrieved memory information, can directly test this proposal.

## Appendix A. Supplementary data

Supplementary data associated with this article can be found, in the online version, at doi:10.1016/j.neuropsychologia.2007.11.015.

## References

- Alessio, A., Bonilha, L., Rorden, C., Kobayashi, E., Min, L. L., Damasceno, B. P., & Cendes, F. (2006). Memory and language impairments and their relationships to hippocampal and perirhinal cortex damage in patients with medial temporal lobe epilepsy. *Epilepsy & Behavior*, *8*, 593–600.
- Baddeley, A. (2003). Working memory: Looking back and looking forward. *Nature Reviews Neuroscience*, *4*, 829–839.
- Bates, E., Wilson, S. M., Saygin, A. P., Dick, F., Sereno, M. I., Knight, R. T., & Dronkers, N. F. (2003). Voxel-based lesion-symptom mapping. *Nature Neuroscience*, *6*, 448–450.
- Baxendale, S. (1998). Amnesia in temporal lobectomy patients: Historical perspective and review. *Seizure*, *7*, 15–24.
- Chou, T.-L., Booth, J. R., Burman, D. D., Bitan, T., Bigio, J. D., Lu, D., & Cone, N. E. (2006). Developmental changes in the neural correlates of semantic processing. *NeuroImage*, *29*, 1141–1149.
- Corbetta, M., Kincade, M. J., Lewis, C., Snyder, A. Z., & Sapir, A. (2005). Neural basis and recovery of spatial attention deficits in spatial neglect. *Nature Neuroscience*, *8*, 1603–1610.
- Corbetta, M., & Shulman, G. L. (2002). Control of goal-directed and stimulus-driven attention in the brain. *Nature Reviews Neuroscience*, *3*, 201–215.
- Damasio, H., & Damasio, A. R. (1989). *Lesion analysis in neuropsychology*. New York: Oxford University Press.
- Desimone, R., & Duncan, J. (1995). Neural mechanisms of selective visual attention. *Annual Review of Neuroscience*, *18*, 193–222.
- Dobbins, I. G., Kroll, N. E., Tulving, E., Knight, R. T., & Gazzaniga, M. S. (1998). Unilateral medial temporal lobe memory impairment: Type deficit, function deficit, or both? *Neuropsychologia*, *36*, 115–127.
- Friedman, D., & Johnson, R. J. (2000). Event-related potential (ERP) studies of memory encoding and retrieval: A selective review. *Microscopy Research and Technique*, *51*, 6–28.
- Henik, A., Rubinstein, O., & Anaki, D. (Eds.). (2005). *Word norms for the Hebrew language (Hebrew)*. Beersheba: Ben Gurion University of the Negev.
- Kobayashi, Y., & Amaral, D. G. (2003). Macaque monkey retrosplenial cortex. II. Cortical afferents. *Journal of Comparative Neurology*, *466*, 48–79.
- Lavenex, P., Suzuki, W. A., & Amaral, D. G. (2002). Perirhinal and parahippocampal cortices of the macaque monkey: Projections to the neocortex. *Journal of Comparative Neurology*, *447*, 394–420.
- Lee, T. M., Yip, J. T., & Jones-Gotman, M. (2002). Memory deficits after resection from left or right anterior temporal lobe in humans: A meta-analytic review. *Epilepsia*, *43*, 283–291.
- Mah, L., Arnold, M. C., & Grafman, J. (2004). Impairment of social perception associated with lesions of the prefrontal cortex. *American Journal of Psychiatry*, *161*, 1247–1255.
- Maratos, E. J., Allan, K., & Rugg, M. D. (2000). Recognition memory for emotionally negative and neutral words: An ERP study. *Neuropsychologia*, *38*, 1452–1465.
- Mecklinger, A. (1998). On the modularity of recognition memory for object form and spatial location: A topographic ERP analysis. *Neuropsychologia*, *36*, 441–460.
- Milner, B. (1972). Disorders of learning and memory after temporal lobe lesions in man. *Clinical Neurosurgery*, *19*, 421–446.
- Moscovitch, M., & Winocur, G. (2002). The frontal cortex and working memory. In D. T. Stuss & R. T. Knight (Eds.), *Principles of frontal lobe function* (pp. 188–209). New York: Oxford University Press.
- Müller, N. G., & Knight, R. T. (2006). The functional neuroanatomy of working memory: Contributions of human brain lesion studies. *Neuroscience*, *139*, 51–58.
- Rockland, K. S., & Van Hoesen, G. W. (1999). Some temporal and parietal cortical connections converge in CA1 of the primate hippocampus. *Cerebral Cortex*, *9*, 232–237.
- Rossi, S., Pasqualetti, P., Zito, G., Vecchio, F., Cappa, S. F., Miniussi, C., Babiloni, C., & Rossini, P. M. (2006). Prefrontal and parietal cortex in human episodic memory: An interference study by repetitive transcranial magnetic stimulation. *European Journal of Neuroscience*, *23*, 793–800.
- Rugg, M. D. (1995). ERP studies of memory. In M. D. Rugg & M. G. H. Coles (Eds.), *Electrophysiology of mind: Event-related brain potentials and cognition* (pp. 113–127). Oxford: Oxford University Press.
- Rugg, M. D. (2004). Retrieval processing in human memory: Electrophysiological and fMRI evidence. In M. S. Gazzaniga (Ed.), *The cognitive neurosciences III* (pp. 727–738). Cambridge: The MIT Press.
- Rugg, M. D., & Henson, R. N. A. (2002). Episodic memory retrieval: An (event-related) functional imaging perspective. In A. E. Parker, E. L. Wilding, & T. Bussey (Eds.), *The cognitive neuroscience of memory encoding and retrieval* (pp. 3–37). New York: Psychology Press.
- Rugg, M. D., Schloerscheidt, A. M., Doyle, M. C., Cox, C. J. C., & Patching, G. R. (1996). Event-related potentials and the recollection of associative information. *Cognitive Brain Research*, *4*, 297–304.
- Saito, K., Kimura, K., Minematsu, K., Shiraiishi, A., & Nakajima, M. (2003). Transient global amnesia associated with an acute infarction in the retrosplenium of the corpus callosum. *Journal of the Neurological Sciences*, *210*, 95–97.
- Saur, D., Lange, R., Baumgaertner, A., Schraknepper, V., Willmes, K., Rijntjes, M., & Weiller, C. (2006). Dynamics of language reorganization after stroke. *Brain*, *129*, 1371–1384.
- Schloerscheidt, A. M., & Rugg, M. D. (1997). Recognition memory for words and pictures: An event-related potential study. *NeuroReport*, *8*, 3281–3284.
- Shannon, B. J., & Buckner, R. L. (2004). Functional-anatomic correlates of memory retrieval that suggest nontraditional processing roles for multiple distinct regions within posterior parietal cortex. *Journal of Neuroscience*, *24*, 10084–10092.
- Soroker, N., Kasher, A., Giora, R., Batori, G., Corn, C., Gil, M., & Zaidel, E. (2005). Processing of basic speech acts following localized brain damage: A new light on the neuroanatomy of language. *Brain and Cognition*, *57*, 214–217.
- Spiers, H. J., Maguire, E. A., & Burgess, N. (2001). Hippocampal amnesia. *Neurocase*, *7*, 357–382.
- Squire, L. R., Stark, C. E. L., & Clark, R. E. (2004). The medial temporal lobe. *Annual Review of Neuroscience*, *27*, 279–306.
- Suzuki, W. A., & Amaral, D. G. (1994). Perirhinal and parahippocampal cortices of the macaque monkey: Cortical afferents. *Journal of Comparative Neurology*, *350*, 497–533.
- Tulving, E. (1983). *Elements of episodic memory*. New York: Oxford University Press.
- Tzourio-Mazoyer, N., Landeau, B., Papathanassiou, D., Crivello, F., Etard, O., Delcroix, N., Mazoyer, B., & Joliot, M. (2002). Automated anatomical labeling of activations in SPM using a macroscopic anatomical parcellation of the MNI MRI single-subject brain. *NeuroImage*, *15*, 273–289.
- Valenstein, E., Bowers, D., Verfaellie, M., Heilman, K. M., Day, A., & Watson, R. T. (1987). Retrosplenial amnesia. *Brain*, *110*, 1631–1646.
- Vincent, J. L., Snyder, A. Z., Fox, M. D., Shannon, B. J., Andrews, J. R., Raichle, M. E., & Buckner, R. L. (2006). Coherent spontaneous activity identifies a hippocampal-parietal memory network. *Journal of Neurophysiology*, *96*, 3517–3531.
- Wagner, A. D., Shannon, B. J., Kahn, I., & Buckner, R. L. (2005). Parietal lobe contributions to episodic memory retrieval. *Trends in Cognitive Sciences*, *9*, 445–453.
- Wager, T. D., & Smith, E. E. (2003). Neuroimaging studies of working memory: A meta-analysis. *Cognitive Affective & Behavioral Neuroscience*, *3*, 255–274.
- Wechsler, D. (1997). *Wechsler memory scale* (3rd ed.). San Antonio, TX: The Psychological Corporation.
- Yasuda, Y., Watanabe, T., Tanaka, H., Tadashi, I., & Akiguchi, I. (1997). Amnesia following infarction in the right retrosplenial region. *Clinical Neurology and Neurosurgery*, *99*, 102–105.