

# Cytokeratin polypeptide expression in a cloacogenic carcinoma and in the normal anal canal epithelium

Rivka Levy<sup>1</sup>, Bernard Czernobilsky<sup>2</sup>, and Benjamin Geiger<sup>3</sup>

<sup>1</sup> Department of Pathology, Faculty of Medicine, Technion, Haifa, Israel

<sup>2</sup> Department of Pathology, Kaplan Hospital, Rehovot, Israel (affiliated to the Medical School of the Hebrew University and Hadassah, Jerusalem)

<sup>3</sup> Department of Chemical Immunology, Weizmann Institute of Science, Rehovot, Israel

Received September 12, 1990 / Accepted November 23, 1990

**Summary.** The aim of the present study was to explore the origin of cloacogenic carcinoma in the anal canal by immunohistochemical methods. We compared cytokeratin polypeptide expression of a cloacogenic carcinoma to normal anal epithelia, to anal squamous cell carcinoma and to basal and squamous cell carcinoma of the skin, using a battery of monoclonal anti-cytokeratin, polypeptide-specific antibodies. Our results indicate that cloacogenic carcinoma expresses cytokeratin polypeptides similar to those of the basal layer of anal squamous epithelium, of the anal transitional zone epithelium and of a layer of basal cells in the anal glands. Thus we concluded that each of the above cell types may be the cell of origin of cloacogenic carcinoma.

**Key words:** Cloacogenic carcinoma – Anal – Canal – Cytokeratins – Immunohistochemistry

## Introduction

Neoplasms of the anorectal region are uncommon (Sawyers 1972; White et al. 1984) and only 2–3% of them are cloacogenic carcinomas, originating in the transitional zone of the anal canal (Kheir et al. 1972; Klots et al. 1967; Levin et al. 1977). Grinvalsky and Helwig in 1956 drew attention to the transitional zone epithelium as a probable remnant of the embryonic cloaca and named the tumour arising from this tissue “transitional cloacogenic carcinoma”. The most common growth pattern is that of nests of elongated and angulated cells growing invasively in long finger-like extensions. In the better differentiated lesions, distinct palisading is present at the periphery of the cellular nests presenting a basaloid appearance. The classic transitional type cloacogenic carcinoma has cells that are larger than those of the basaloid variety. Well-differentiated cloacogenic cancer closely resembles basal cell carcinoma. Various degrees of squa-

mous differentiation may also be present (Gillespie and Mackay 1978; Grodsky 1969; Kheir et al. 1972; Pang and Morson 1967). The tumour occasionally presents as a squamous cell carcinoma, often containing basaloid elements.

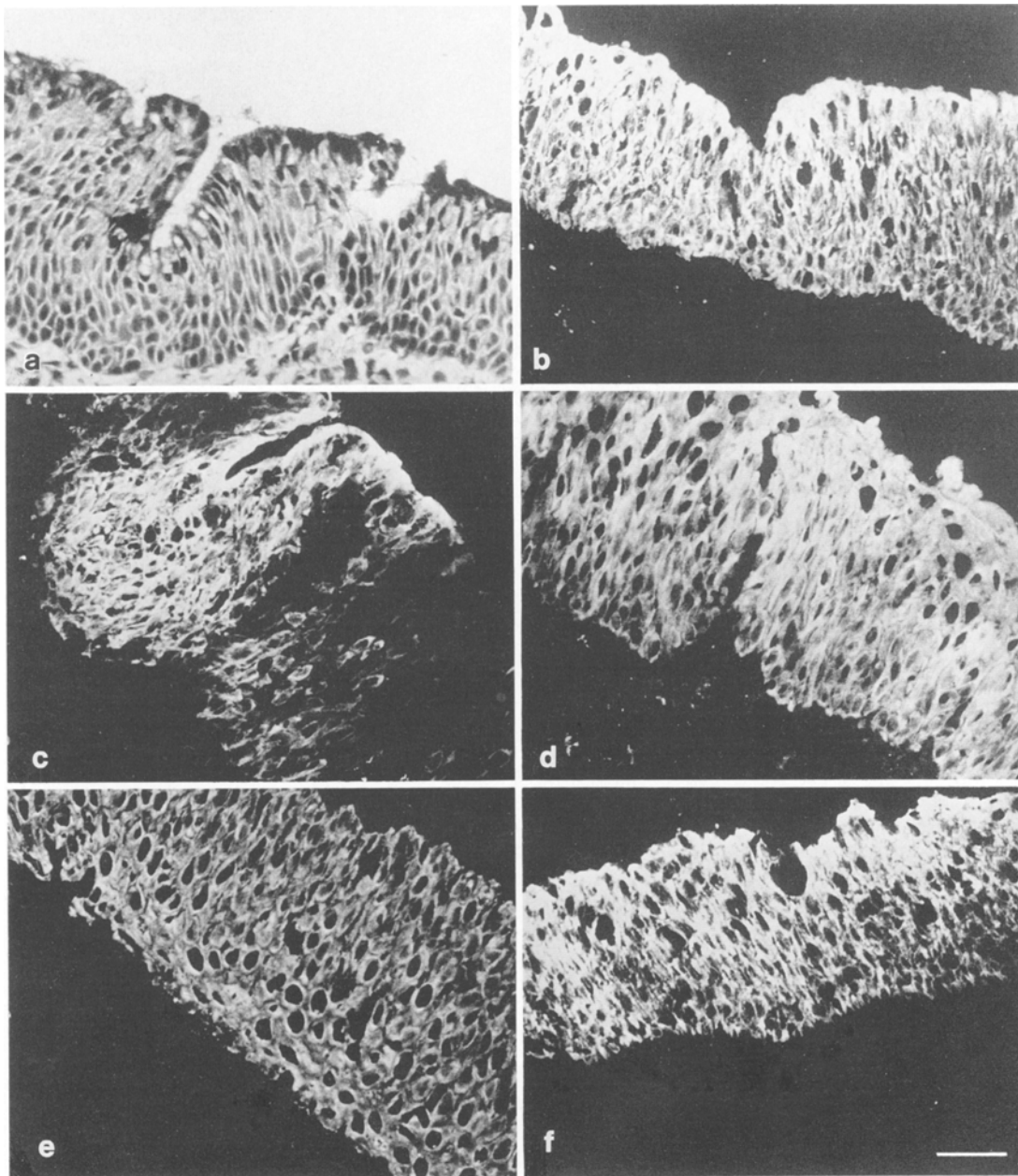
Recent studies have indicated that intermediate filaments can be used as reliable histogenetic markers in normal and malignant tissues (Anderton 1981; Debus et al. 1982; Franke et al. 1979, 1982; Fuchs 1983; Lazarides 1980, 1982; Moll et al. 1981; Osborn and Weber 1983; Osborn et al. 1984a, b; Ramaekers et al. 1983; Vogel and Gown 1984). Moll et al. (1982, 1983) found a very complex pattern of cytokeratin polypeptide expression in gel-electrophoretic analysis of a cloacogenic carcinoma. The tumour contained cytokeratin polypeptides 1, 5, 6, 7, 8, 13, 15, 17 and 19 with small amounts of 10, 11 and 14.

In the present study we examined cytokeratin polypeptide expression in a cloacogenic carcinoma. We compared the results to cytokeratin polypeptide expression of squamous cell carcinoma of the anus as well as to basal and squamous cell carcinoma of the skin and to normal anal mucosa, by immunohistochemical techniques, using a battery of monoclonal anti-cytokeratin polypeptide-specific antibodies.

## Materials and methods

Tissue samples of five cases from the normal anorectal area, obtained from surgical specimens from one case of cloacogenic carcinoma, from a patient with squamous cell carcinoma of the anus, as well as from two cases of typical basal cell carcinoma and two cases of moderately differentiated squamous cell carcinoma of the skin were obtained from operations performed at the Kaplan Hospital in Rehovot. The tissues were snap frozen in isopentane pre-cooled in liquid nitrogen and stored at –70° C until used as previously described (Blobel et al. 1984; Franke et al. 1979). For histological examination, the tissues were fixed in 10% buffered formalin, embedded in paraffin and stained with haematoxylin and eosin.

A series of anti-cytokeratin polypeptide-specific monoclonal antibodies all from Bio-Makor (Rehovot, Israel) were used in this study: KG-8.13 – a broad spectrum anticytokeratin antibody react-



**Fig. 1.** Haematoxylin and eosin (H&E) (a) and immunofluorescence staining of normal human anal transitional zone epithelium monoclonal cytokeratin-specific antibodies (b–f): **b** KM-4.62, **c** KS-B17.2, **d** KS-2.1, **e** KS-1A3 and **f** KS-8.58. Note positive homo-

geneous staining of the transitional zone epithelium with antibodies KM-4.62, KS-2.1, KS-1A3 and KS-8.58. Antibody KS-B17.2 stained positively some areas of the epithelium, while negative reaction is seen in other areas. Bar, 25 µm

ing with cytokeratin polypeptides 1, 5, 6, 7, 8, 10, 11 and 18 and present in all human epithelial cells (Gigi et al. 1982).

KM-4.62 – reacting with human cytokeratin polypeptide 19, which is present in simple epithelia and in the basal layer of squamous epithelia (Gigi-Leitner and Geiger 1986).

KS-B17.2 – reacting with human cytokeratin polypeptide 18, present in simple epithelia (Levy et al. 1988).

KS-8.58 – reacting with human cytokeratin polypeptides 13 and 16, which are present in non-keratinizing squamous epithelium (Huszar et al. 1986).

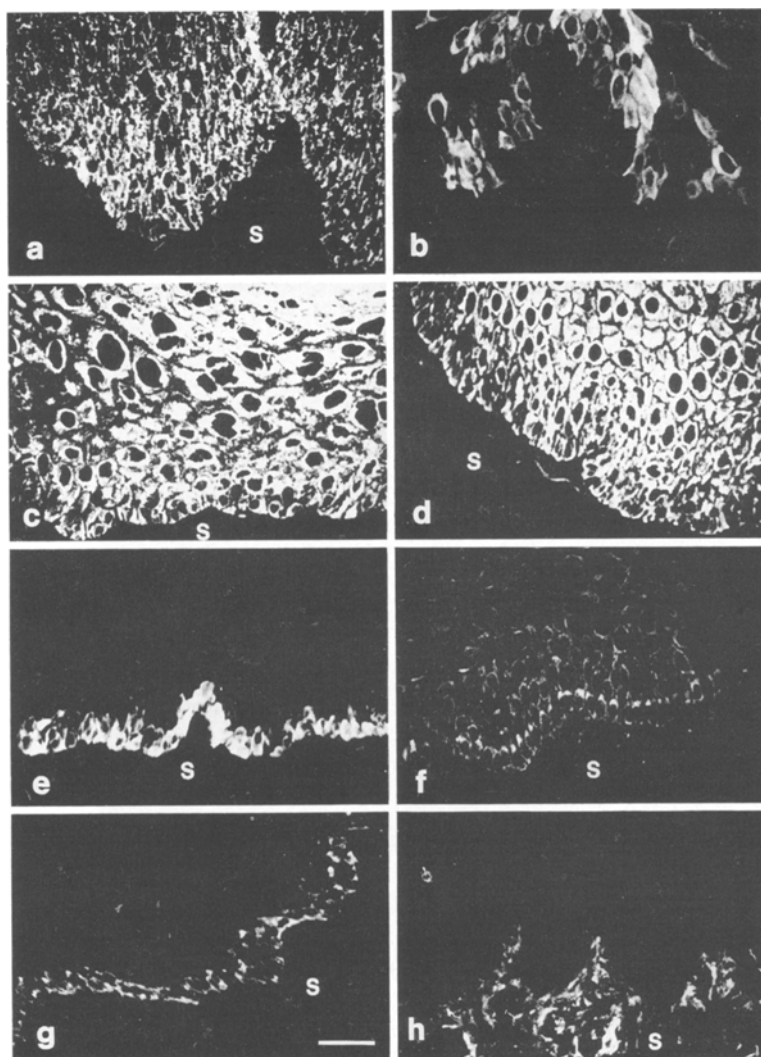
KS-1A3 – reacting with human cytokeratin polypeptide 13, which is present in non-keratinizing squamous epithelium. In addition, it stains the basal layer of epidermis as well as myoepithelial and reserve cells of glands (Levy et al. 1988).

KK-8.60 – reacting with human cytokeratin polypeptides 10 and 11, which are present in epidermis staining keratinizing squamous epithelium (Huszar et al. 1986).

KS-2.1 – reacts with several human simple and squamous epithelium. In endocervical glands it stains specifically the reserve and ciliated cells. The specificity of this antibody is unknown because it does not react with any cytokeratin in Western blot analysis (Levy et al. 1988).

The different monoclonal antibodies used were applied as undiluted hybridoma culture supernatants. The secondary antibodies were affinity-purified goat antibodies raised against mouse (Fab')<sub>2</sub>, and conjugated to lissamine rhodamine sulphonyl chloride as previously described (Brandzaeg 1973; Geiger and Singer 1979).

For immunohistochemistry tissue samples were frozen in isopen-



**Fig. 2.** Immunofluorescence staining of normal human surface squamous epithelium of anus with monoclonal antibodies: **a** KG-8.13, **b** KK-8.60, **c** KS-1A3, **d** KS-8.58, **e** KM-4.62, **f** KS-2.1. Note positive homogeneous staining of all cells with antibodies KG-8.13, KS-1A3 and KS-8.58. The basal layer was strongly stained with antibodies KM-4.62, and KS-2.1. Antibody KK-8.60 stained only individual cells positively. Bar, 25  $\mu$ m

tane precooled in liquid nitrogen and cut at 5  $\mu$ m using a Jung-Reichert cryostat (Heidelberg, FRG). The frozen sections were acetone fixed and immunolabelled as previously described (Blobel et al. 1984; Franke et al. 1979). For immunofluorescence analysis sections were stained and examined with a Zeiss Axiophot microscope equipped for epifluorescence, using a planapochromat  $\times 40/1.0$  oil iris objective. Adjacent sections were stained with haematoxylin and eosin.

## Results

The cytokeratin polypeptide expression in the normal anal canal was manifest as follows.

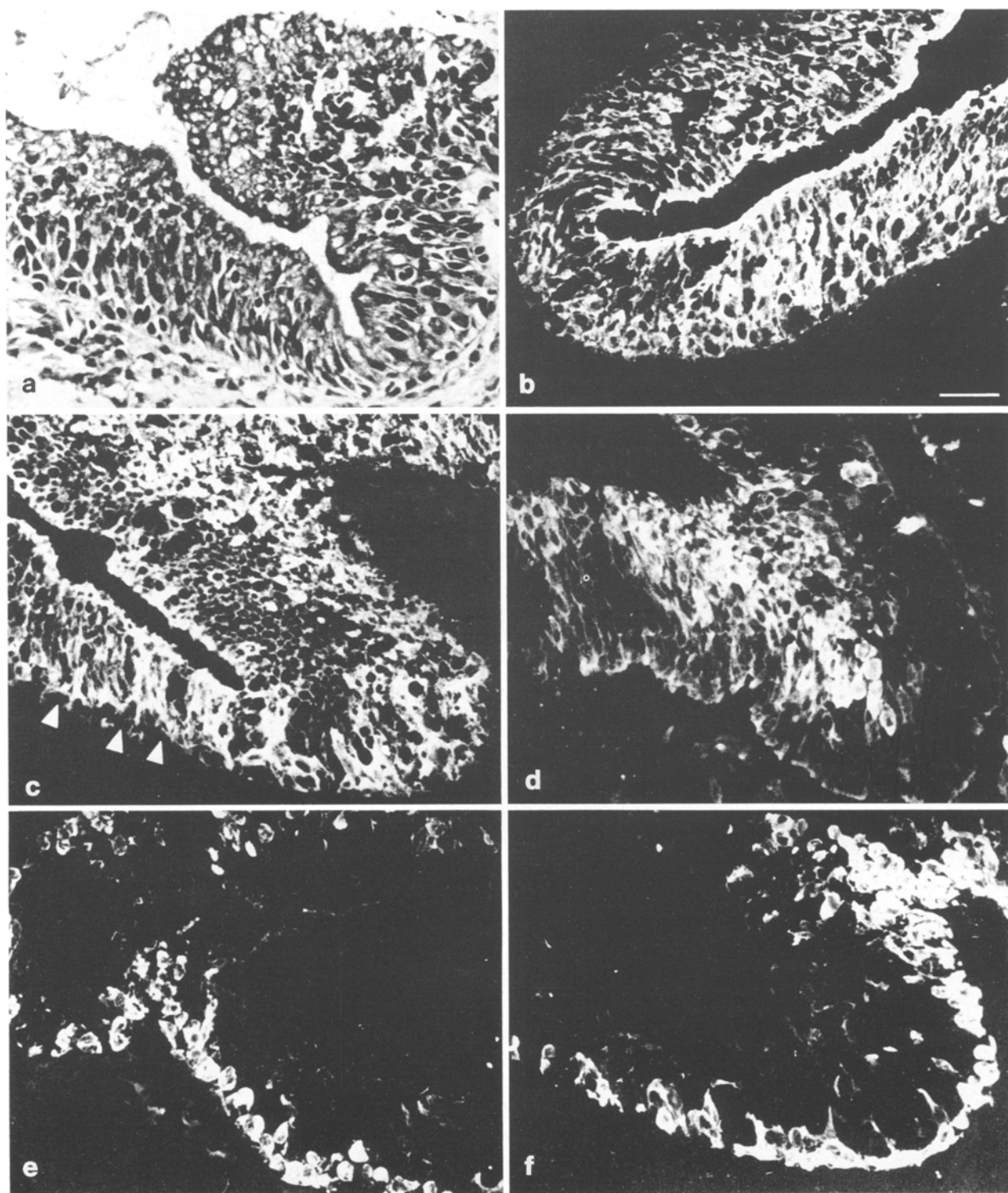
All the epithelial elements were positively stained with the broad spectrum antibody KG-8.13 and were negative with the antibody to vimentin.

The transitional epithelium of the anus was homogeneously stained with antibodies KM-4.62 (Fig. 1b), KS-2.1 (Fig. 1d), KS-1A3 (Fig. 1e) and KS-8.58 (Fig. 1f). Antibody KS-B17.2 stained the transitional epithelium unevenly (Fig. 1c); some areas reacted strongly, others were weak or negative. No labelling was obtained with antibody KK-8.60.

The rectal glands stained positively with antibodies KG-8.13, KM-4.62, KS-B17.2 and KS-2.1. No labelling was obtained with antibodies KS-8.58, KK-8.60, and KS-1A3.

Antibodies KG-8.13, KS-1A3 and KS-8.58 showed strong positive staining of the squamous epithelium (Fig. 2a, c and d respectively). Antibodies KM-4.62 and KS-2.1 stained the basal layer of the squamous epithelium (Fig. 2e and f respectively). Antibody KK-8.60 stained strongly groups of supra-basal cells (Fig. 2b).

The epithelium lining the superficial portions of the anal glands stained similarly to that of the anal transitional epithelium. The deeper parts of the glands are lined by simple columnar epithelium (Fig. 3a). All the cells of the anal glands were positively stained with antibody KM-4.62 (Fig. 3b). Antibodies KS-1A3 and KS-8.58 stained only a layer of basal cells (Fig. 3e, f) located underneath the luminal epithelium. KS-B17.2 stained positively most of the anal gland cells except for basal cells (Fig. 3c). Heterogeneous staining was also obtained with antibody KS-2.1, which stained strongly some cells mainly close to the lumen (Fig. 3d). No labelling was obtained with antibody KK-8.60.



**Fig. 3.** H&E (a) and immunofluorescence staining with cytokeratin-specific monoclonal antibodies of normal anal canal glands (b-f): b KM-4.62, c KS-B17.2, d KS-2.1, e KS-1A3 and f KS-8.58. Note positive homogeneous staining of all anal gland cells with antibody KM-4.62. Antibody KS-2.1 stained mainly cells facing

the lumen; antibody KS-B17.2 stained most anal gland cells except for one layer of basally located cells (arrowheads). Most cells are not stained with antibodies KS-8.58 and KS-1A3, while basal cells stained positively. Bar, 25  $\mu$ m

Table 1 compares the cytokeratin pattern between cloacogenic carcinoma and anal and rectal epithelial tissues.

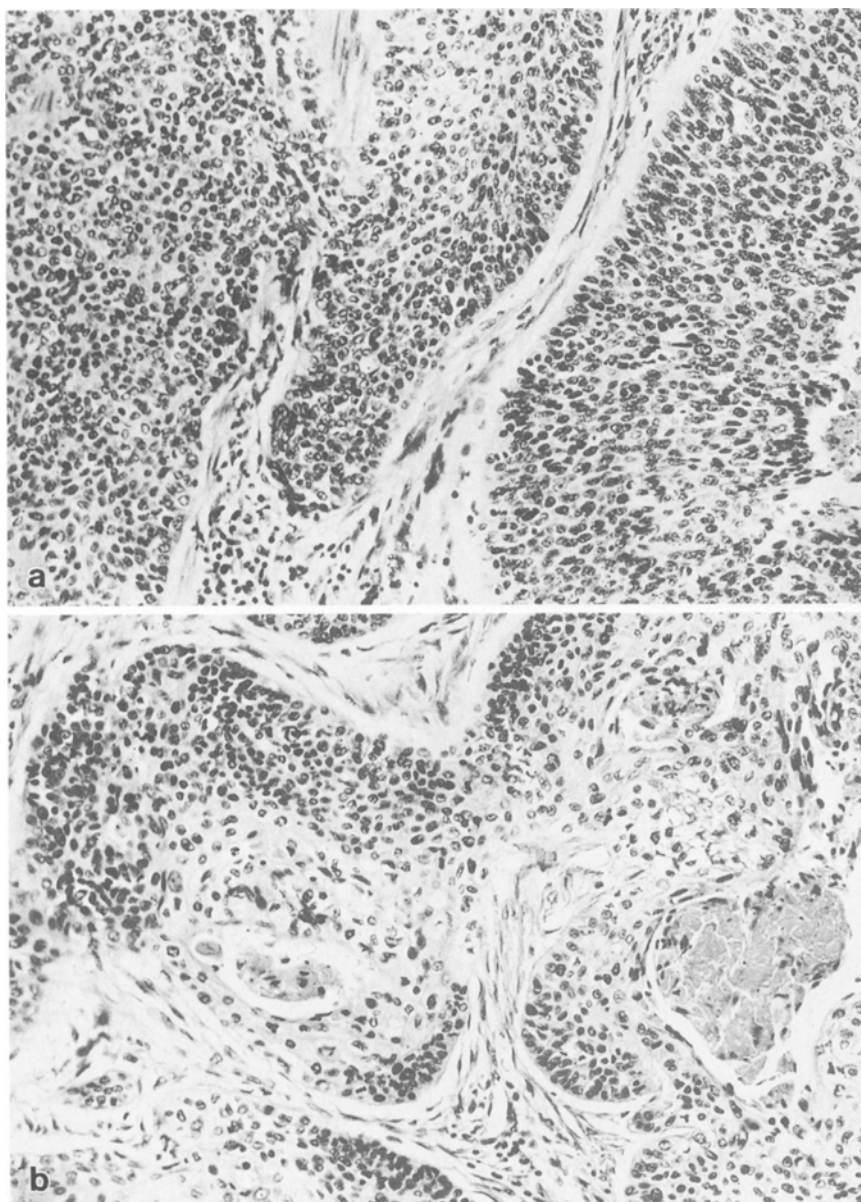
The cloacogenic carcinoma examined was in a specimen consisting of a segment of the rectum and anus.

About 3 cm above the anus there was a soft grey ulcerated infiltrating mass of 5.5 cm in greatest diameter. The tumour was composed of epithelial nests of varying size separated by fibrous connective tissue (Fig. 4a, b). In many of these nests there was central eosinophilic necro-

**Table 1.** Comparison of cytokeratin profile of cloacogenic carcinoma and normal anal and rectal epithelial tissues

|          | Cloacogenic carcinoma | Squamous epithelium |       | Transitional epithelium | Anal glands |       | Rectal glands |
|----------|-----------------------|---------------------|-------|-------------------------|-------------|-------|---------------|
|          |                       | basal               | supra |                         | basal       | supra |               |
| KG-8.13  | +                     | +                   | +     | +                       | +           | +     | +             |
| KM-4.62  | +                     | +                   | —     | +                       | +           | +     | +             |
| KS-B17.2 | +h                    | —                   | —     | +h                      | ±           | +     | +             |
| KS-1A3   | +                     | +                   | +     | +                       | +           | —     | —             |
| KS-8.58  | +s                    | +                   | +     | +                       | +           | —     | —             |
| KS-8.60  | +s                    | —                   | +h    | —                       | —           | —     | —             |
| KS-2.1   | +s                    | +                   | —     | +                       | ±           | +     | +             |

h, Heterogeneous staining, some groups of cells were positively stained; s, sporadic staining of cells

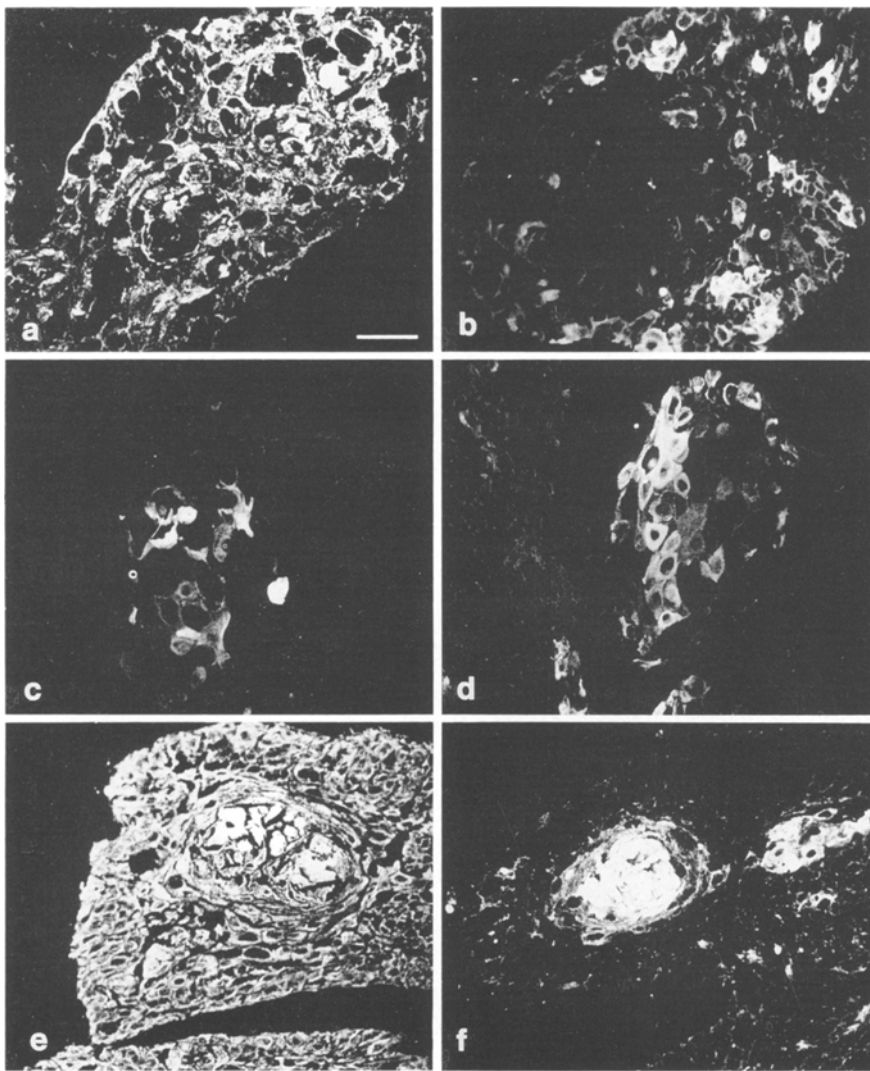


**Fig. 4a, b.** Light microscopic appearance of cloacogenic carcinoma. **a** Tumour showing features of transitional type epithelium. **b** Tumour nests showing basaloid cells at periphery with squamous differentiation towards the centre. H&E,  $\times 150$

sis with cyst formation (Fig. 4b). Squamous differentiation with keratinization was often noticed. In the central area of the tumour nests there was occasional pearl formation. Moreover some of the tumour nests were entire-

ly squamous. Most tumour cells showed round to oval nuclei with dispersed chromatin and single nucleoli, although in some areas the nuclei were elongated. It was noted that nuclear pleomorphism was slight and mitoses





**Fig. 5.** Immunofluorescence staining of cloacogenic carcinoma with monoclonal antibodies: **a** KM-4.62, **b** KS-B17.2, **c** KS-2.1, **d** KK-8.60, **e** KS-1A3, and **f** KS-8.58. Note positive homogeneous staining of all tumour cells with antibodies KM-4.62 and KS-1A3. There is uneven staining with antibodies KS-B17.2, KS-2.1, KK-8.60 and KS-8.58. Bar, 25 µm

were frequent. The tumour cell nests did not merge with the overlying anal skin or rectal mucosa. Anal glands were not identified.

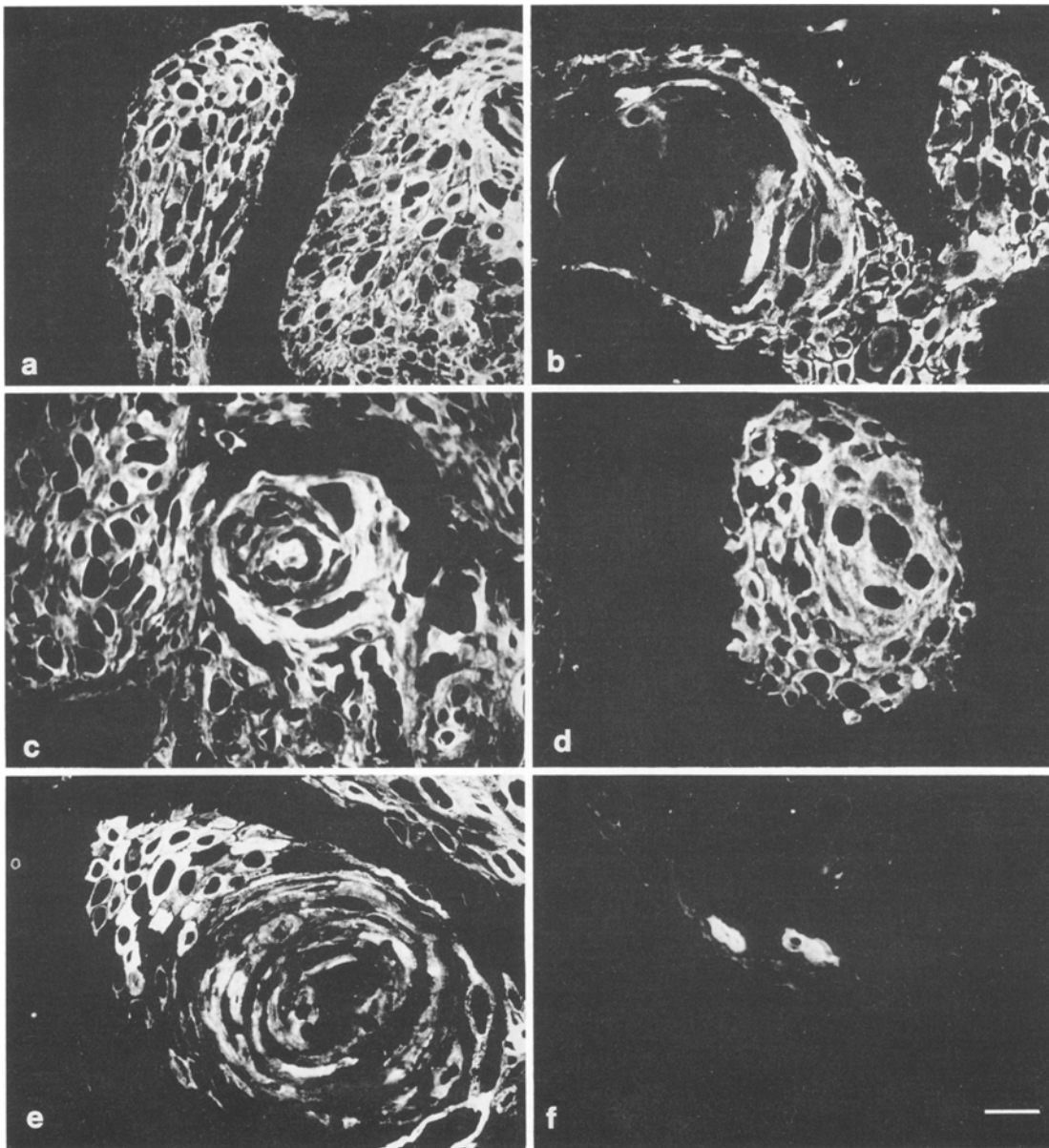
All nests were labelled weakly with antibody KS-8.58, while squamous tumour cells stained strongly (Fig. 5f). All neoplastic cells showed strong reaction with antibodies KS-1A3 and KM-4.62 (Fig. 5e and a respectively). Labelling of tumour cells with antibody KK-8.60 was obtained in few cells of tumour nests and in areas of pearls (Fig. 5c). Antibody KS-2.1 stained individual cells among the squamous area (Fig. 5d). While some tumour cell nests stained with antibody KS-B17.2, others were either negative or only partially stained (Fig. 5b).

In squamous cell carcinoma of anal canal the broad spectrum antibody KG-8.13 stained all tumour cells positively (Fig. 6a). All cells were also positive with antibodies KS-2.1 (Fig. 6b), KS-1A3 (Fig. 6c) and KS-8.58 (Fig. 6e). Antibody KK-8.60 stained the tumour strongly in the centre, while the cells at the periphery of cell nests were negative (Fig. 6d). KM-4.62 stained few, scat-

tered tumour cells. No staining was obtained with antibody KS-B17.2.

Antibody KS-8.58 stained weakly most of the cells in both cases of basal cell carcinoma of the skin with strong focal staining of individual cell. With antibody KM-4.62 there was no positive staining in one case and little to strong labelling in different parts of the tumour in the second case. In both cases strong positive staining of tumour cells was obtained with antibody KS-1A3; antibody KS-2.1 stained the cells weakly; antibody KK-8.60 stained the large cell nests of tumours strongly and groups of cells in the centre of small nests. No staining was obtained with antibody KS-B17.2.

Antibodies KG-8.13, KS-1A3 and KS-8.58 stained positively all the tumour cells in squamous cell carcinoma of the skin with stronger staining of the pearls. No staining was obtained with antibodies KK-8.60, KM-4.62 and KS-B17.2 (data not shown). Results with antibodies KS-8.58, KM-4.62 and KK-8.60 were similar to those previously reported (Gigi-Leitner and Geiger 1986; Huszar et al. 1986; Thomas et al. 1984).



**Fig. 6.** Immunofluorescence staining of squamous cell carcinoma of anus with monoclonal antibodies: **a** KG-8.13, **b** KS-2.1, **c** KS-1A3, **d** KK-8.60, **e** KS-8.58 and **f** KM-4.62. Note positive homogeneous staining of all tumour cells with antibodies KG-8.13, KS-2.1,

KS-1A3 and KS-8.58. Antibody KK-8.60 stained the tumour cells strongly, while cells in the periphery of nests were negative. Staining with KM-4.62 was of individual few cells. Bar, 25 µm

**Table 2.** Comparison of cytokeratin profile of cloacogenic carcinoma and other neoplasms

|          | Cloacogenic carcinoma | Anal squamous cell carcinoma | Squamous cell carcinoma of skin | BCC of skin |
|----------|-----------------------|------------------------------|---------------------------------|-------------|
| KG-8.13  | +                     | +                            | +                               | +           |
| KM-4.62  | +                     | +s                           | —                               | —           |
| KS-B17.2 | +h                    | —                            | —                               | —           |
| KS-1A3   | +                     | +                            | +                               | +           |
| KS-8.58  | +h                    | +                            | +                               | +           |
| KS-8.60  | +s                    | —                            | —                               | —           |
| KS-2.1   | +s                    | +                            | ND                              | +           |

h, Heterogeneous staining; s, staining of individual cells only; BCC, basal cell carcinoma; ND, not done

Table 2 compares the cytokeratin pattern between the various tumours.

## Discussion

The site of origin of the rare cloacogenic carcinoma is still uncertain. It has been proposed that these neoplasms arise from the transitional epithelium of the anal canal (Gillespie and MacKay 1978; Grinvalsky and Helwig 1956; Otto et al. 1979). In the present study the same pattern of staining of both cloacogenic carcinoma and normal transitional anal epithelium was seen with most antibodies except for antibody KK-8.60. The latter showed no staining of transitional epithelium, but strong

staining of individual cells in the central squamous areas of the tumour. Thus it was concluded that cytokeratin expression of transitional epithelium is very similar to that of cloacogenic carcinoma. The difference in staining with antibody KK-8.60 might indicate that these cells present within the tumour nests possess a higher potential of squamous differentiation. Furthermore comparison of the cytokeratin expression of cloacogenic carcinoma with the normal squamous epithelium of the anal region revealed that the tumour may arise from the basal layer of squamous epithelium. In addition there is the possibility that the anal glands may be the tissue of origin of the cloacogenic tumour, especially a layer of cells located underneath the luminal cells, which are positively labelled with antibodies KS-8.58 and KS-1A3. This possibility may explain the occasional presence of this neoplasm within the wall of the rectum or anal canal without superficial mucosal involvement as well as at locations higher or lower than the narrow transitional zone (Kheir et al. 1972). These basal cells present a certain resemblance to the reserve cells of the endocervix, both by their morphology as well as by their cytokeratin expression (Gigi-Leitner and Geiger 1986; Levy et al. 1988).

Previous biochemical analysis of cloacogenic carcinoma by Moll et al. (1982, 1983) indicated that this neoplasm contained cytokeratins 1, 5, 6, 7, 8, 13, 15, 17 and 19 with small amounts of polypeptides 10, 11 and 14 indicating a complex pattern of differentiation. Our results were largely in agreement with those of Moll et al., providing, in addition, information concerning the spatial distribution of the various polypeptides. Cytokeratin polypeptide 18 was present in some tumour cells according to our immunocytochemical studies but was not identified biochemically by Moll et al. (1982, 1983). The explanation for this discrepancy might be that the small amounts of cytokeratin polypeptide 18 present could not be detected in gel electrophoresis, or that nests of tumour tested by Moll et al. (1982, 1983) did not contain this particular cytokeratin polypeptide. In the centre of nests some peripheral tumour cells showing clearly squamous differentiation expressed cytokeratin 18 which is typical of simple epithelium. A similar phenomenon was observed in an ovarian Brenner tumour (Lifschitz-Mercer et al. 1988), in which cell staining for cytokeratin 18 was present at the periphery of squamous nests, suggesting polarity in the transformation from transitional to squamous elements.

According to Gillespie and MacKay (1978) two principle variants of cloacogenic tumours are generally recognized: the more common, well-differentiated transitional form, which is associated with relatively favourable prognosis (Grinvalsky and Helwig 1956); and a second "basaloid" variant bearing histological resemblance to cutaneous basal cell carcinoma (Pang and Morson 1967). Although there are morphological similarities between the basaloid variant and basal cell carcinoma, there is a striking contrast in the biological behaviour of these tumours. The basaloid cloacogenic tumour behaves aggressively and has a poor prognosis (Grodsky 1969; Kheir et al. 1972). For this reason we thought

that it might be of interest to compare the cytokeratin polypeptide expression of the two types of tumour. In spite of some differences noted between the two cases of basal cell carcinoma we observed some similarities as well as significant differences between basal cell and cloacogenic carcinomas. Both expressed cytokeratin polypeptide 13. The most significant differences could be detected in expression of cytokeratin 19 (KM-4.62) and 10/11 (KK-8.60). The former labelled the cloacogenic carcinoma extensively but was almost absent in the better-differentiated basal cell carcinoma. Cytokeratin polypeptides 10 and 11, which appeared only in few cells in cloacogenic carcinoma, were abundant in basal cell carcinoma. This may be explained on the basis of the theory of Sun et al. (1984), according to which there is a correlation between the molecular weight of the cytokeratins and the tissue state of differentiation. Dougherty and Evans (1985) and Cullen and Sanders (1966) suggested that cloacogenic carcinoma should be classified as a squamous cell carcinoma. The present study, based on cytokeratin polypeptide comparison with cutaneous squamous cell carcinoma, does not support this hypothesis.

In conclusion, we have mapped the cytokeratin profile of the epithelial elements of the normal anal canal and of a cloacogenic carcinoma as well as of morphologically related tumours. On the basis of cytokeratin staining we believe that cloacogenic carcinoma represents a distinct group of tumours which may arise from either the transitional zone of the anal epithelium, from the basal layer of the anal glands or from the basal layer of the anal squamous epithelium.

*Acknowledgement.* B. Geiger is the E. Neter Professor for Cell and Tumor Biology.

## References

- Anderton BH (1981) Intermediate filaments: a family of homologous structure. *J Muscle Res Cell Motil* 2:141-146
- Blobel GA, Moll R, Franke WW, Vogt-Moykopf (1984) Cytokeratin in normal lung and lung carcinomas. I. Adenocarcinomas, squamous cell carcinomas and cultured cell lines. *Virchows Arch [B]* 45:407-429
- Brandzaeg P (1973) Conjugates of immunoglobulin G with different fluorophores. I. Characterization by anionic exchange chromatography. *Scand J Immunol* 2:273-290
- Cullen PK, Sanders RJ (1966) Cloacogenic anorectal carcinoma. *Dis Colon Rectum* 9:1-12
- Debus E, Weber K, Osborn M (1982) Monoclonal cytokeratin antibodies that distinguish simple from stratified squamous epithelia: characterization on human tissues. *EMBO J* 1:1641-1647
- Dougherty BG, Evans HL (1985) Carcinoma of the anal canal: a study of 79 cases. *Am J Clin Pathol* 83:159-164
- Franke WW, Appelhaus B, Schmid E, Freudenstein C, Osborn M, Weber K (1979) Identification and characterization of epithelial cells in mammalian tissues by immunofluorescence microscopy using antibody to prekeratin. *Differentiation* 15:7-25
- Franke WW, Schmid E, Schiller DL, Winter S, Jarasch ED, Moll R, Denke H, Jackson BW, Illmensee K (1982) Differentiation-related patterns of expression of proteins of intermediate-sized filaments in tissues and cultured cells. *Cold Spring Harb Symp Quant Biol* 46:432-453



- Fuchs E (1983) Evolution and complexity of the genes encoding the keratins of human epidermal cells. *J Invest Dermatol* 81:141s-144s
- Geiger B, Singer SJ (1979) Participation of  $\alpha$ -actinin in the capping of membrane component. *Cell* 16:213-222
- Gigi O, Geiger B, Eshhar Z, Moll R, Schmid E, Winter S, Schiller DL, Franke WW (1982) Detection of cytokeratin determinant common to diverse epithelial cells by a broadly cross-reacting monoclonal antibody. *EMBO J* 1:1429-1437
- Gigi-Leitner O, Geiger B (1986) Antigenic interrelationship between 40 kilodalton cytokeratin polypeptide and desmoplakin. *Cell Motil Cytoskeleton* 6:628-639
- Gigi-Leitner O, Geiger B, Levy R, Czernobilsky B (1986) Cytokeratin expression in squamous metaplasia of the human uterine cervix. *Differentiation* 31:191-205
- Gillespie JJ, MacKay B (1978) Histogenesis of cloacogenic carcinoma. Fine structure of anal transitional epithelium and cloacogenic carcinoma. *Hum Pathol* 9:579-587
- Grinvalsky HT, Helwig EB (1956) Carcinoma of the anorectal junction. I. Histological considerations. *Cancer* 9:480-488
- Grodsky L (1969) Current concepts on cloacogenic transitional cell anorectal cancers. *JAMA* 207:2057-2061
- Huszar M, Gigi-Leitner O, Moll R, Franke WW, Geiger B (1986) Monoclonal antibodies to various acidic (type 1) cytokeratins of stratified epithelia. Selective markers for stratification and squamous cell carcinomas. *Differentiation* 31:141-153
- Kheir S, Hickely LC, Martin RG, MacKay S, Gallager MD (1972) Cloacogenic carcinoma of the anal canal. *Arch Surg* 104:407-415
- Klots RG, Pamukcoglu T, Souillard DH (1967) Transitional cloacogenic carcinoma of the anal canal. *Cancer* 20:1727-1745
- Lazarides E (1980) Intermediate filaments as mechanical integrators of cellular space. *Nature* 283:249-255
- Lazarides E (1982) Intermediate filaments: a chemically heterogeneous, developmentally regulated class of proteins. *Annu Rev Biochem* 51:219-250
- Levin SE, Cooperman H, Freilich M, Lomas M, Kaplan L (1977) Transitional cloacogenic carcinoma of the anus. *Dis Colon Rectum* 20:17-23
- Levy R, Czernobilsky B, Geiger B (1988) Subtyping of epithelial cells of normal and metaplastic human uterine cervix, using polypeptide-specific cytokeratin antibodies. *Differentiation* 39:185-194
- Lifschitz-Mercer B, Czernobilsky B, Schezen E, Dgani R, Leitner O, Geiger B (1988) Selective expression of cytokeratin polypeptides in various epithelia of human Brenner tumor. *Hum Pathol* 19:640-650
- Moll R, Franke WW, Schiller DL, Geiger B, Krepler R (1981) The catalog of human cytokeratins: pattern of expression in normal epithelia, tumors and cultured cells. *Cell* 31:11-24
- Moll R, Von Bassewitz DB, Schulz U, Franke WW (1982) An unusual type of cytokeratin filament in cell of human cloacogenic carcinoma derived from the anorectal transitional zone. *Differentiation* 22:25-40
- Moll R, Krepler R, Franke WW (1983) Complex cytokeratin polypeptide pattern observed in certain human carcinomas. *Differentiation* 23:256-259
- Osborn M, Weber K (1983) Tumor diagnosis by intermediate filaments typing: a novel tool for surgical pathology. *Lab Invest* 48:372-394
- Osborn M, Debus E, Weber K (1984a) Monoclonal antibodies specific for vimentin. *Eur J Cell Biol* 34:137-143
- Osborn M, Altmannsberger M, Debus E, Weber K (1984b) Conventional and monoclonal antibodies to intermediate filament proteins in human tumor diagnosis. In: *Cancer Cells, The Transformed Phenotype*. Cold Spring Harbor Laboratory, New York, vol. 1, pp 191-200
- Otto HF, Gebbers J-O, Winkler R (1979) Untersuchungen zur Ultrastruktur der transitionalen Cloacogenen Carcinome der Recto-analen Grenzregion. *Virchows Arch [A]* 381:223-239
- Pang LSC, Morson BC (1967) Basaloid carcinoma of the anal canal. *J Clin Path* 20:128-135
- Ramaekers FCS, Huysmans A, Moesker O, Kant A, Jap P, Herman C, Vooijs P (1983) Monoclonal antibody to keratin filaments, specific for glandular epithelia and their tumors. *Lab Invest* 49:353-361
- Sawyers LJ (1972) Squamous cell cancer of the perianus and anus. *Surg Clin N Am* 52:935-941
- Sun T-T, Eichner R, Schermer A, Cooper D, Nelson WG, Weiss RA (1984) Classification, expression and possible mechanisms of evolution of mammalian epithelia keratins: a unifying model. In: Levine A, Topp W, Vande Woude GF, Watson JD (eds) *Cancer cell, the transformed phenotype*, vol 1. Cold Spring Harbor Laboratory, New York, pp 169-176
- Thomas P, Said GW, Nash G, Banks-Schlegel S (1984) Profile of keratin proteins in basal and squamous cell carcinomas of skin. *Lab Invest* 36:36-41
- Vogel AM, Gown AM (1984) Monoclonal antibodies to intermediate filament proteins: use in diagnostic surgical pathology. In: Shay J (ed) *Cell and muscle motility*. Plenum, New York, pp 397-402
- White BW, Schneiderman H, Sayre JT (1984) Basal cell carcinoma of the anus: clinical and pathological distinction from cloacogenic carcinoma. *J Clin Gastroenterol* 6:441-446